Thoracic Oncology
Lung Cancer

Ragheed Alturkmani, MD
Interventional pulmonology
Wellstar Pulmonary and critical care medicine
Georgia, USA

Outline

- General overview and classification of thoracic tumors
- Lung cancer
  - Risk factors for lung cancer
  - Diagnosis of lung cancer : symptoms, imaging, tissue diagnosis
  - Staging
  - Treatment
  - Prevention
- Mediastinal tumors
- Pleural tumors

Intrathoracic Tumors

Lung / Airways

Primary pulmonary neoplasms

- Epithelial tumors

  Adenocarcinoma • Squamous • SCLC / NETs
- Salivary gland–type tumors
- Mesenchymal / lymphoid tumors
- Metastases to lung

Pleura / Mesothelium

Primary pleural and mesothelial tumors

- Mesothelioma

  Diffuse • Localized • Mesothelioma in situ
- Other mesothelial tumors
- Solitary fibrous tumor*
- Pleural sarcoma
- Pleural metastases

Mediastinum

Compartment-based tumor spectrum

- Thymic epithelial tumors
  - Thymoma
  - Thymic carcinoma
  - Thymic NET
- Germ-cell tumors
- Lymphoma
- Mesenchymal / neurogenic tumors

Today's focus: Intrathoracic tumors → Lung tumors → Primary lung carcinoma

2021 WHO Classification of Thoracic Malignant Epithelial Tumors

Precursor / glandular lesions
- Atypical adenomatous hyperplasia
- Adenocarcinoma in situ
  - non-mucinous
  - mucinous

Adenocarcinomas
- Minimally invasive adenocarcinoma
- Invasive non-mucinous adenocarcinoma
- Invasive mucinous adenocarcinoma
- Colloid / fetal / enteric-type
- Adenocarcinoma, NOS

Squamous cell carcinomas
- Squamous cell carcinoma, NOS
- Keratinizing / non-keratinizing
- Basaloid squamous cell carcinoma
- Lymphoepithelial carcinoma

Large cell & adenosquamous
- Large cell carcinoma
- Adenosquamous carcinoma

Neuroendocrine tumors
- Carcinoid tumor, NOS
  - typical carcinoid
  - atypical carcinoid
- Small cell carcinoma
- Large cell neuroendocrine carcinoma
- Combined neuroendocrine carcinomas

Salivary gland–type tumors
- Adenoid cystic carcinoma
- Epithelial-myoepithelial carcinoma
- Mucoepidermoid carcinoma
- Hyalinizing clear cell carcinoma
- Myoepithelial carcinoma

Other uncommon groups
- Adenomatoid tumor
- Sclerosing pneumocytoma
- Pulmonary blastoma
- Thoracic SMARCA4-deficient tumor
- NUT carcinoma

Sarcomatoid carcinomas
- Pleomorphic carcinoma
- Giant cell / spindle cell carcinoma
- Pulmonary blastoma / carcinosarcoma

Lung cancer
Bronchogenic cancer

- Second most common cancer in males and females (after prostate, Breast)
- Highest cause of mortality of any other cancer worldwide
- Incidence and trends vary by region
  - Decreasing incidence in US, UK, western coutries in men due to decreasing tobacco smoking
  - Increasing in women in some European countries and in US
  - Follows the trend of tobacco epidemic in each population
  - Projected to increase in incidence due to growing and aging populations and other risk factors

Risk factors for lung cancer

Tobacco and other drugs

Smoking (#1)
Secondhand smoke
Cocaine/marijuana

?? E-cigarettes

Environmental exposures

Wood/coal burning
Asbestos
Radon (#2)
Air pollution (diesel, exhaust, silica)

Certain diseases and treatments

Inflammatory lung diseases
Radiation treatment

Genetic factors

First degree relatives
Race and ethnicity

Others (probable) causes

Diet/supplements
Endocrine disorders
Oncogenic viruses
Opium

Smoking and lung cancer

- Leading cause of lung cancer (85-90%)
- Second-hand smoking
  - Increases risk by 20-30% (CDC)
  - Dose-dependent

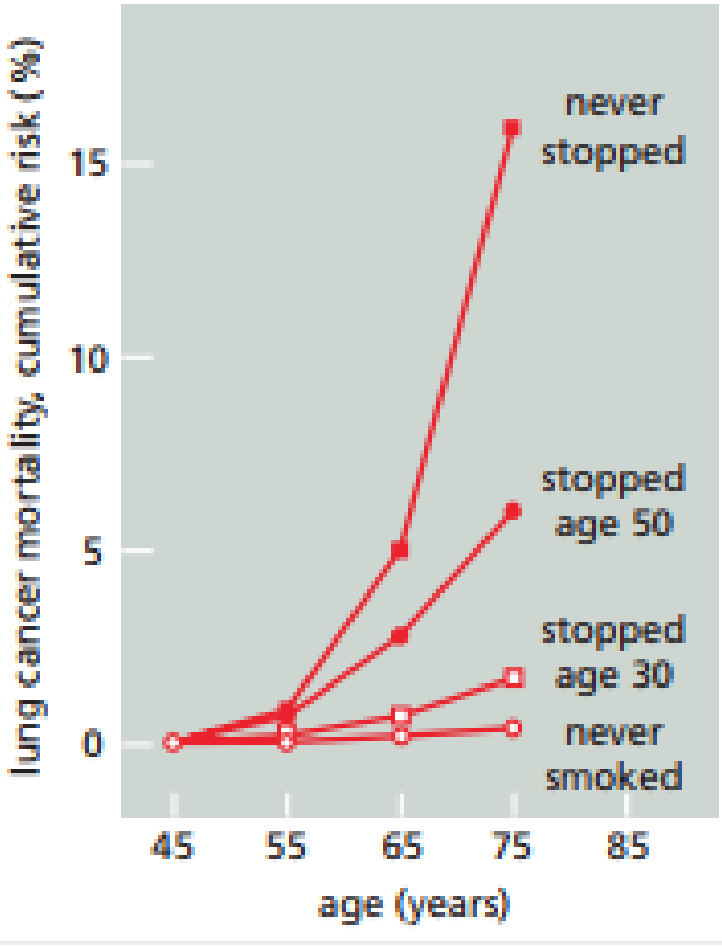

Peto R, Darby S, Deo H, Silcocks P, Whitley E, Doll R.
Smoking, smoking cessation, and lung cancer in the UK since 1950: combination of national statistics with two case-control studies.
BMJ. 2000;321:323–329.

Clinical signs and symptoms of lung cancer

1 Local / Airway Effects

Airway obstruction
Cough • dyspnea • post-obstructive pneumonia • shortness of breath

Endobronchial involvement
Hemoptysis

Pleural involvement
Chest pain • pleural effusion • shortness of breath

2 Regional Invasion / Compression

Recurrent laryngeal nerve
Hoarseness

Brachial plexus / Pancoast
Shoulder or arm pain

Superior vena cava
Face / arm edema → SVC syndrome

Chest wall / mediastinum
Pain or compressive symptoms

3 Paraneoplastic Syndromes

SIADH — classically SCLC
ADH ↑ → hyponatremia

Ectopic ACTH — SCLC
Cushing syndrome • hypokalemia

PTHrP — classically SqCC
Hypercalcemia

Lambert–Eaton — SCLC
Proximal muscle weakness

Clubbing / hypertrophic osteoarthropathy -- SCLC and Adenocarcinoma
Digital clubbing ± periostosis

Lung Cancer Diagnosis
Imaging

- Xray
  - Can provide first clue but insensitive

- CT is the best imaging modality
  - Thin (1 mm) slices, contrast not necessary
  - Screening & Early Detection
  - Tumor Characterization & Morphologic Assessment
  - Staging
  - Guiding Biopsies & Procedural Planning

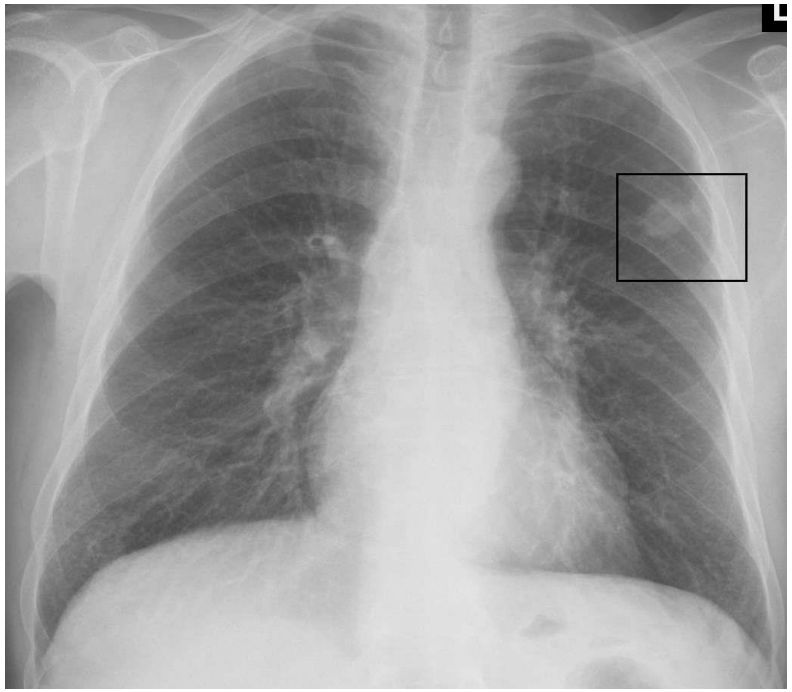

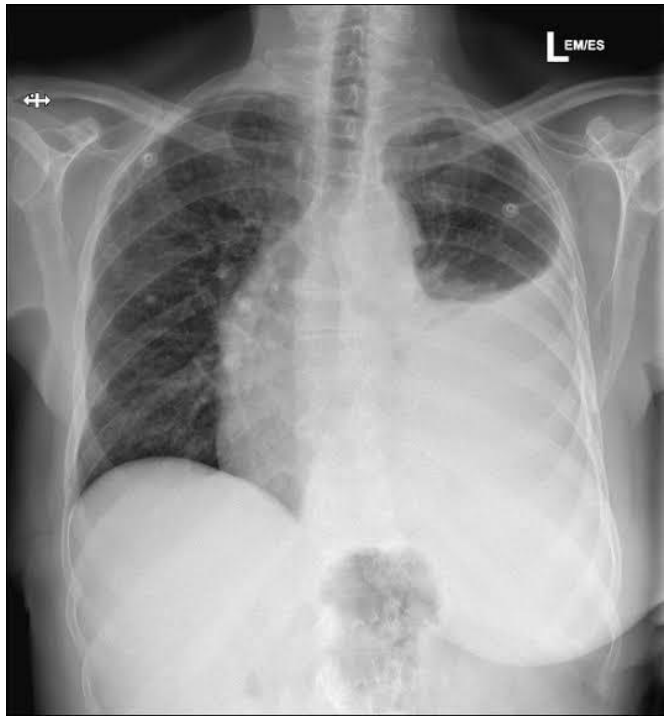

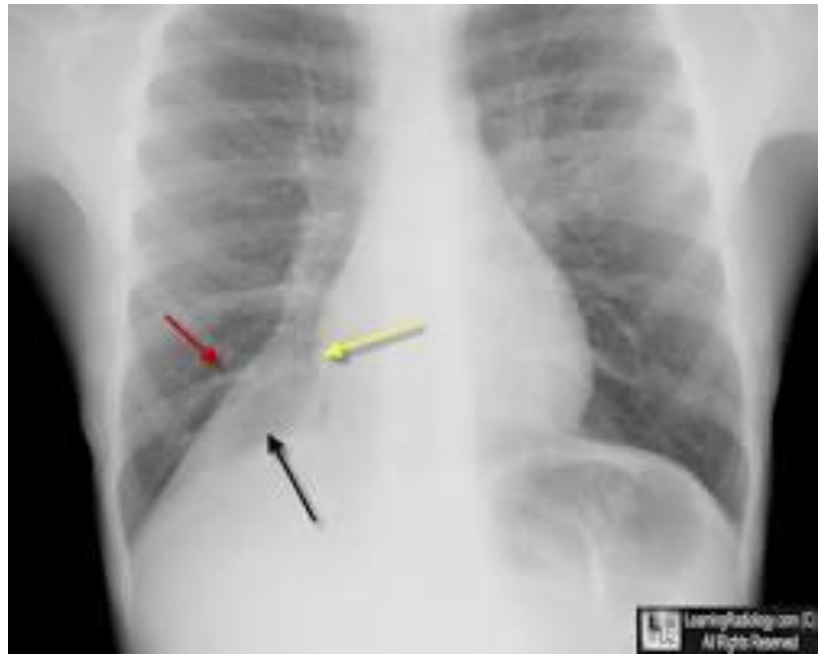

Copyrights apply

Positron Emission Tomography (PET)

- Functional imaging
  - IV Radiotracer: Fluorodeoxyglucose (18F-FDG)
- SUV = Standardized Uptake Value
- SUV=

$$\frac{\text{Tissue Activity Concentration (MBq/g)}}{\text{Injected Dose (MBq)/Body Weight (g)}}$$

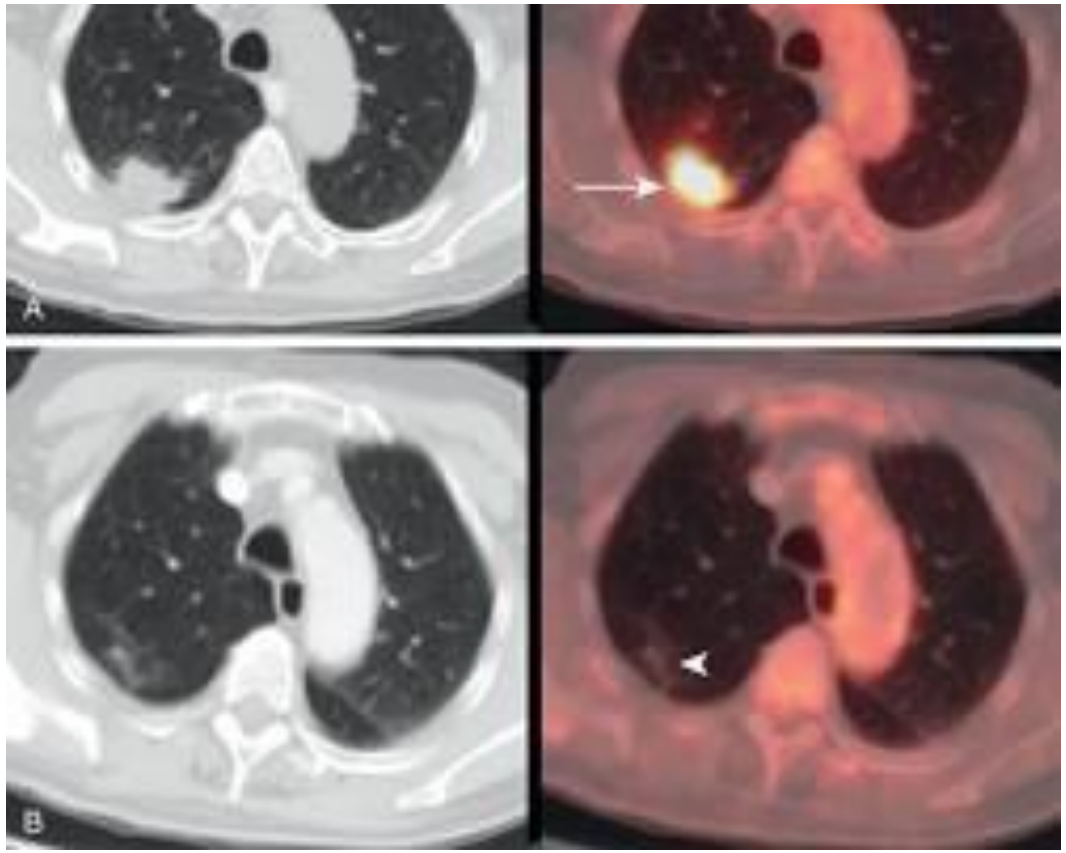

Positron Emission Tomography (PET)

- Role:
  - Evaluating Indeterminate Nodules
  - Selecting Biopsy Targets
  - Staging
  - Therapy Planning & Monitoring
    - Radiation mapping
    - Treatment response evaluation
- False negative:
  - Low metabolic activity/slow growth
  - Small size (<7-10 mm)
  - Hyperglycemia
- False positive:
  - Infection
  - Inflammation

Case example # 1

- 54 years old non smoker found to have a LUL nodule
- **Asymptomatic**
- Robotic bronchoscopy biopsy: Adenocarcinoma of the lung

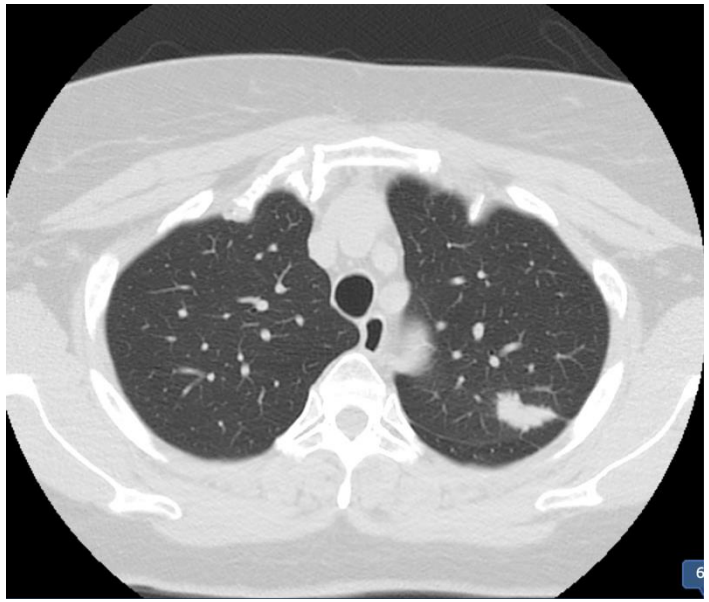

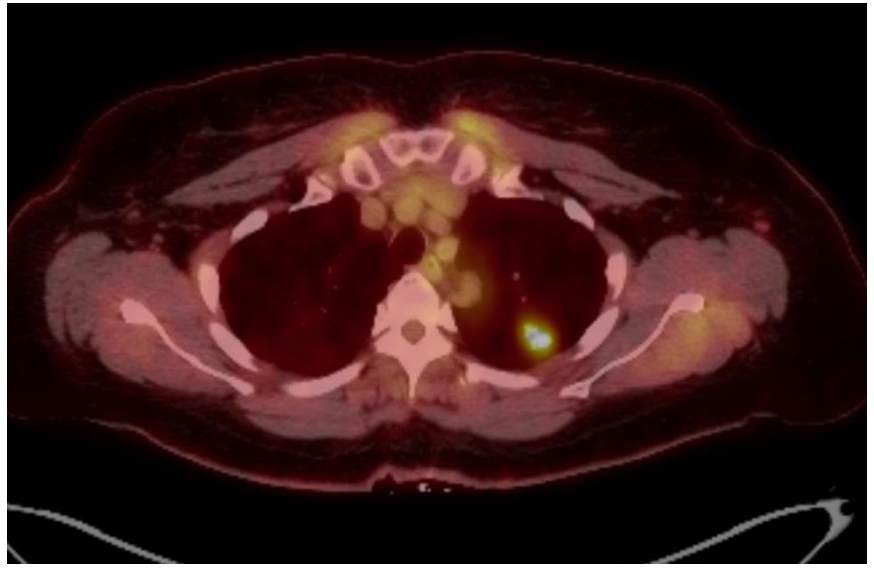

Case example # 2

- 54 year old female
- Subacute cough, dyspnea, hemoptysis, low grade fever

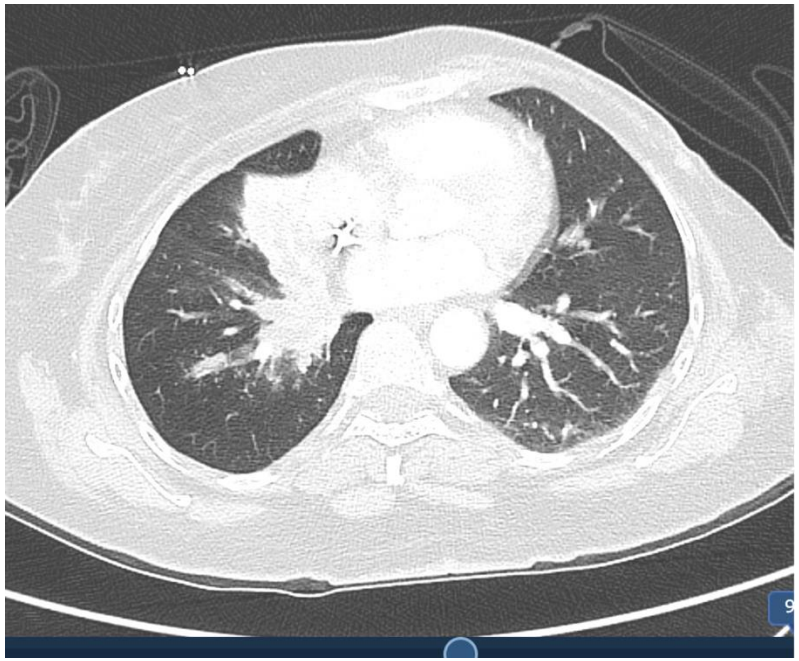

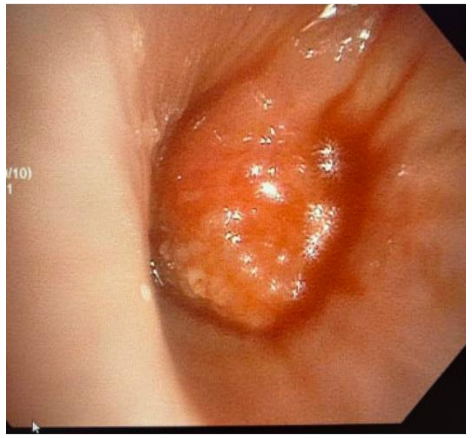

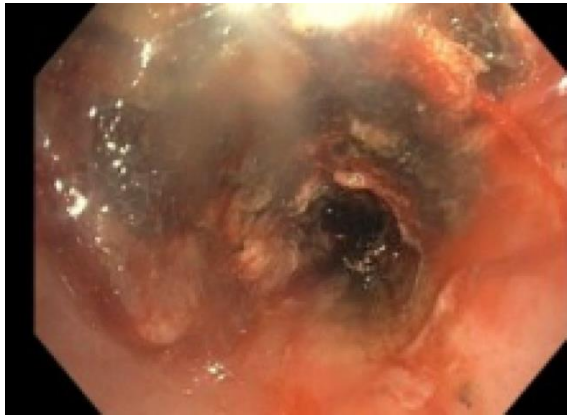

Case example # 3

- 73 y/o ex smoker, lung cancer screening
- Generalized progressive weakness, ataxia, dizziness
- Anti-Neuronal Nuclear Antibody, Type 1 (Anti Hu antibodies)
- EBUS TBNA: small cell lung cancer

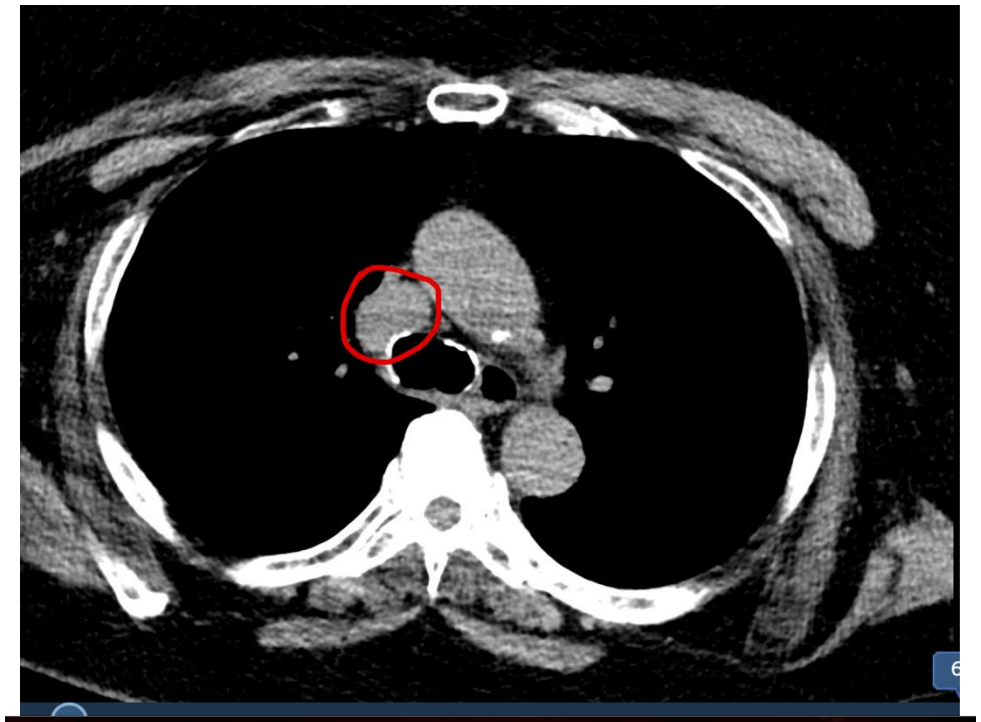



Pulmonary Nodules
Malignancy Risk Factors

- Patient's Age
- Smoking history
- Size
- Location: Upper > lower
- Growth Rate (VDT): 30 – 400 days (avg 200 d)
- Margins: spiculated > lobulated > smooth
- Density: soft tissue > part solid > GGO > fat density
- Calcification pattern
- Contrast enhancement
- History of malignancy

ACCP risk categories

- **Low <5%**
- **Intermediate 5–65%**
- **High >65%**

Nodule growth

Volumetric Doubling Time

- For most cancers 30 – 400 days (avg 200 d)
- Small cell lung cancer is faster
- Solid cancer faster than GGOs
- GGO and part solid Adenocarcinoma slower
- < 20 days = infection, not cancer
- VDT >400 days → likely benign

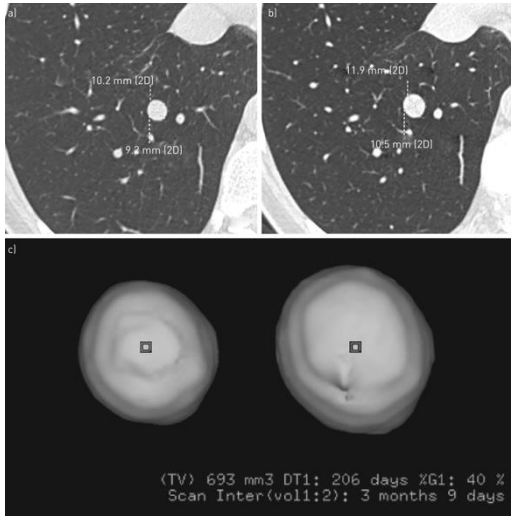

- Volume of a sphere = $4\pi r^3/3$: ↑ 26% diameter = ↑ 2x volume

Nodule boarders

- Risk of malignancy
  - 5x spiculated/ragged margins
  - 2x pleural retraction
  - 70% vessel sign

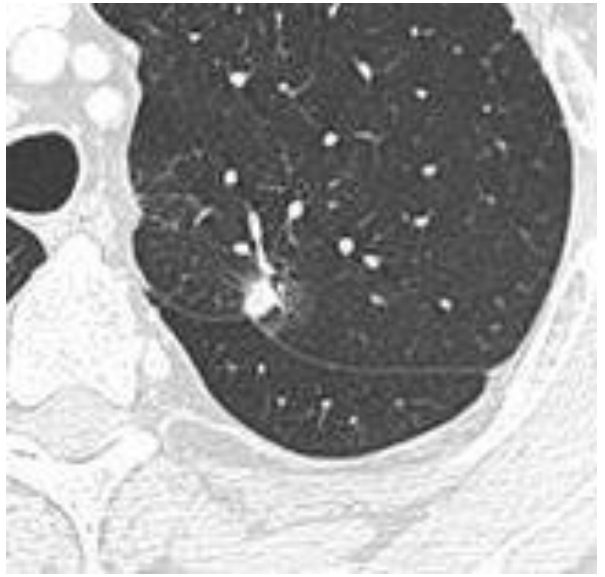



Nodule cavitation

Cavitation

- Wall thickness
  - <4mm: 92% benign
  - >15mm: 95% malignant
  - 5-15 mm: indeterminate
  - Asymmetry in wall thickness*

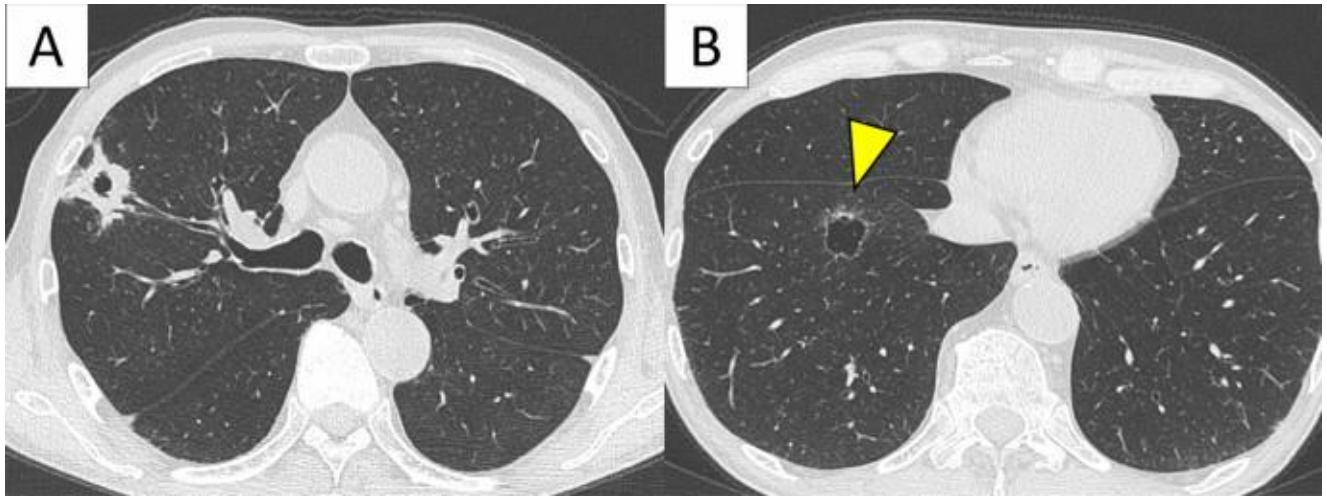

Nodule Calcification

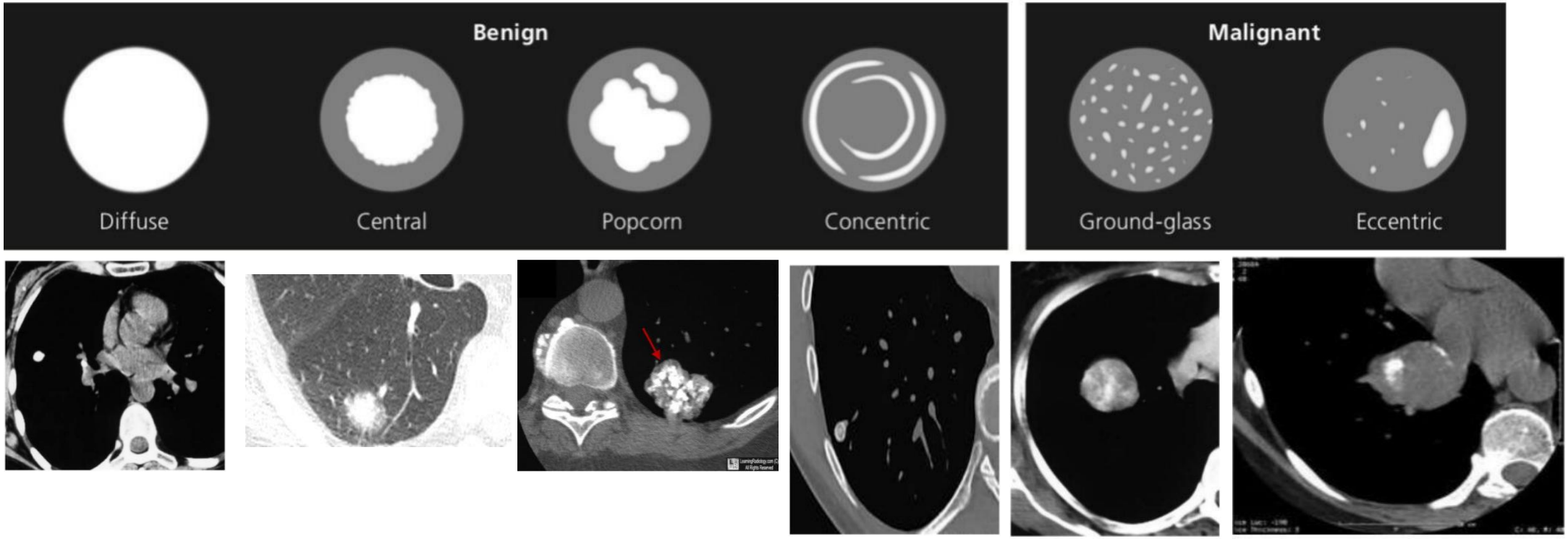

Nodule consistency

Ground glass opacities

- Benign or malignant
- If malignant, Adenocarcinoma most likely
- Solid components increase suspicion of malignancy

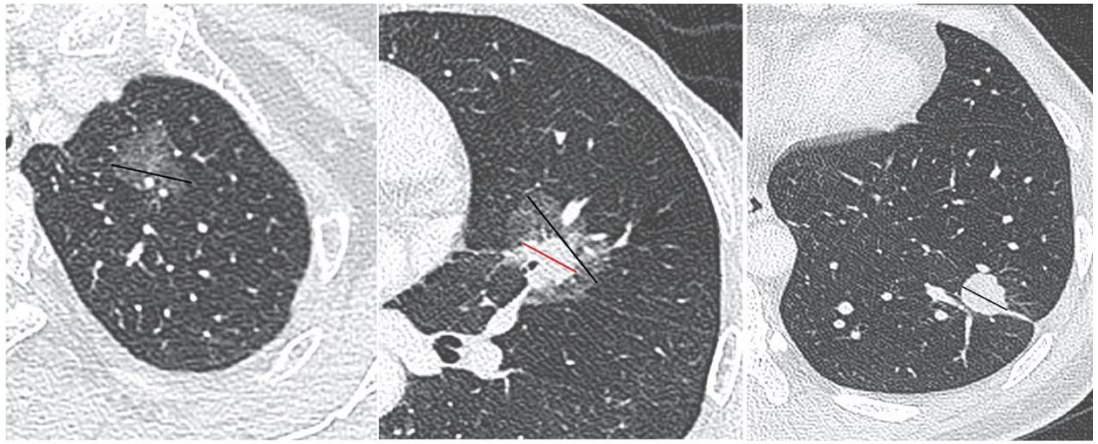

Nodule contrast enhancement

Dynamic contrast enhancement

- Delta HU >15 = higher risk
- Delta HU < 15: high NPV (95%)

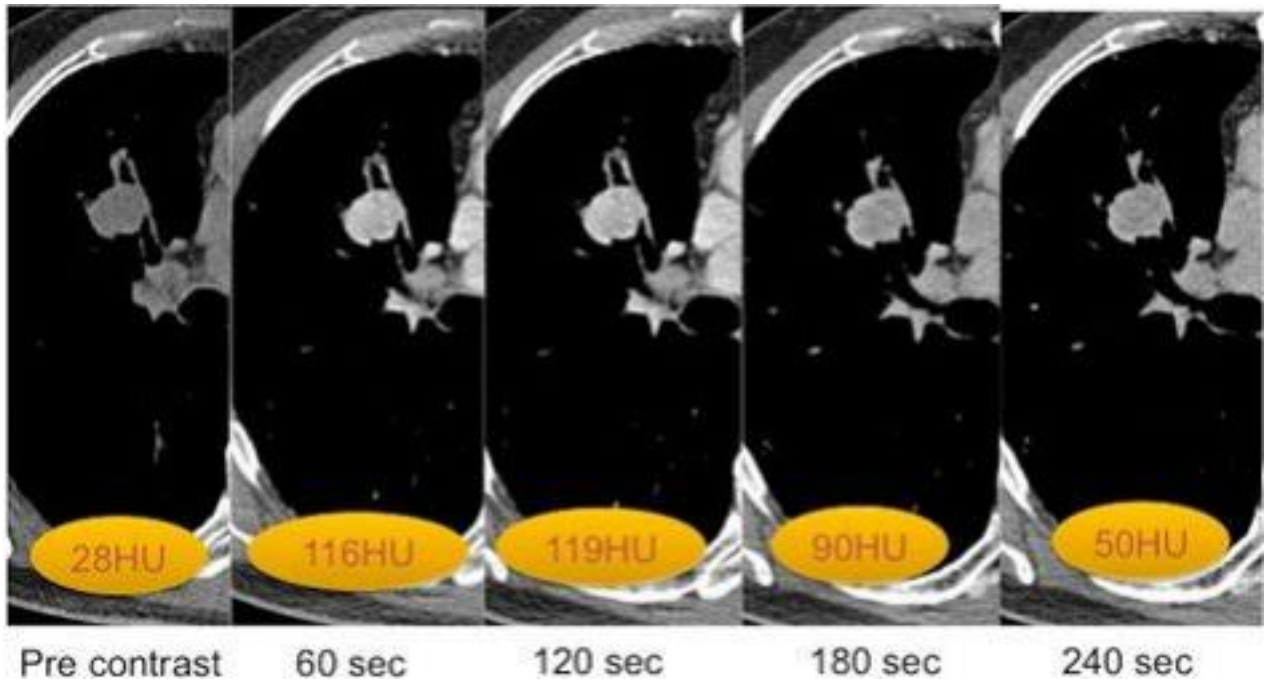

Other Nodule characteristics

- Fat density = benign feature
  - Hamartoma

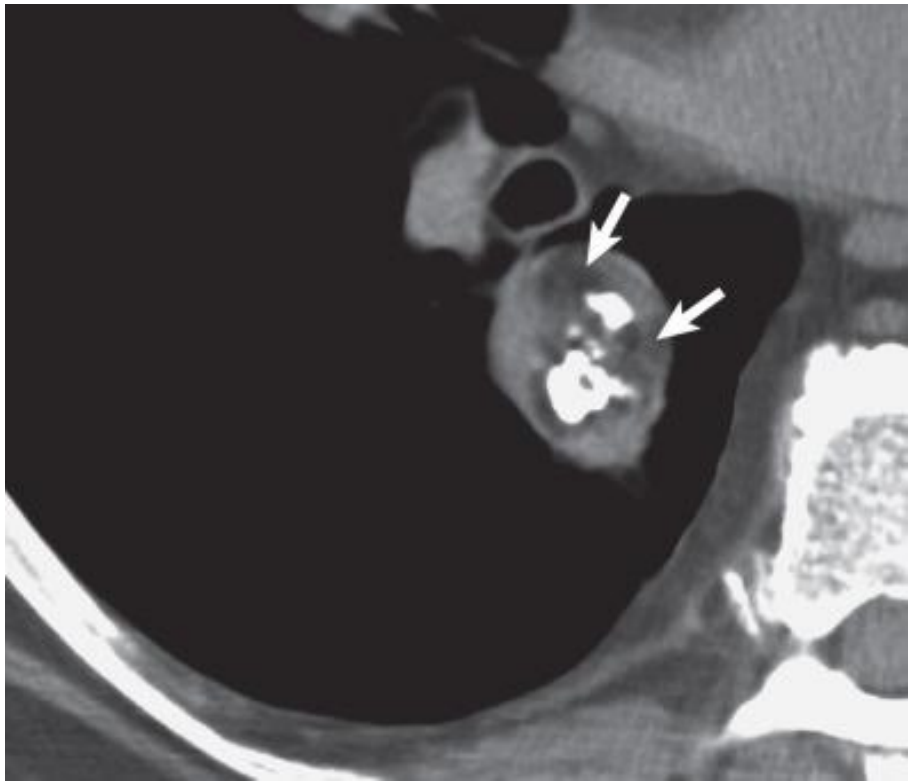

Lung Nodule Quantitative Risk Models

- **Brock model (CT)**
- **Mayo model**
- **Herder (integrates PET)**
- Bayesian
- VCA

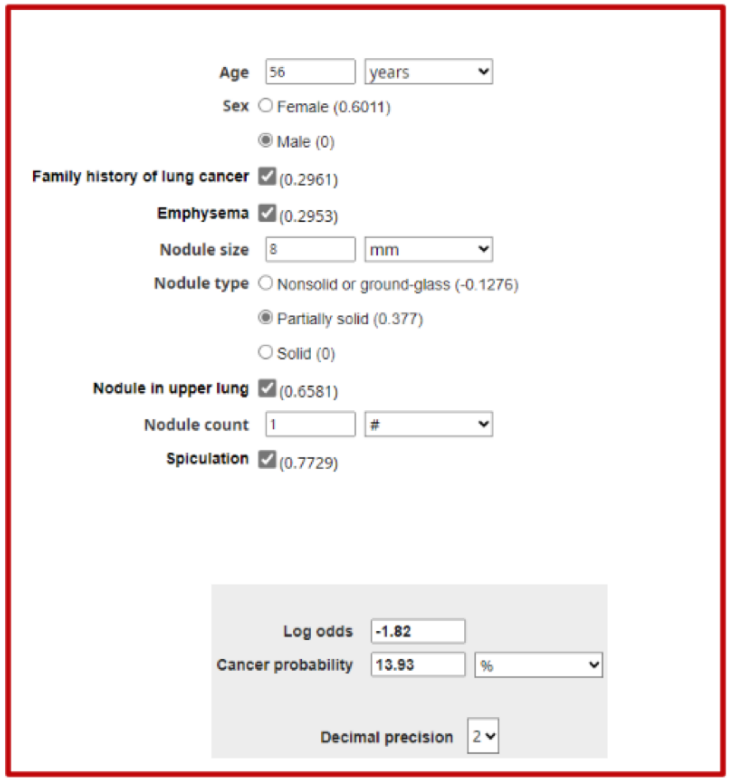

Low <5%

Intermediate 5-65%

High >65%

Lung Nodule Diagnostic Approach

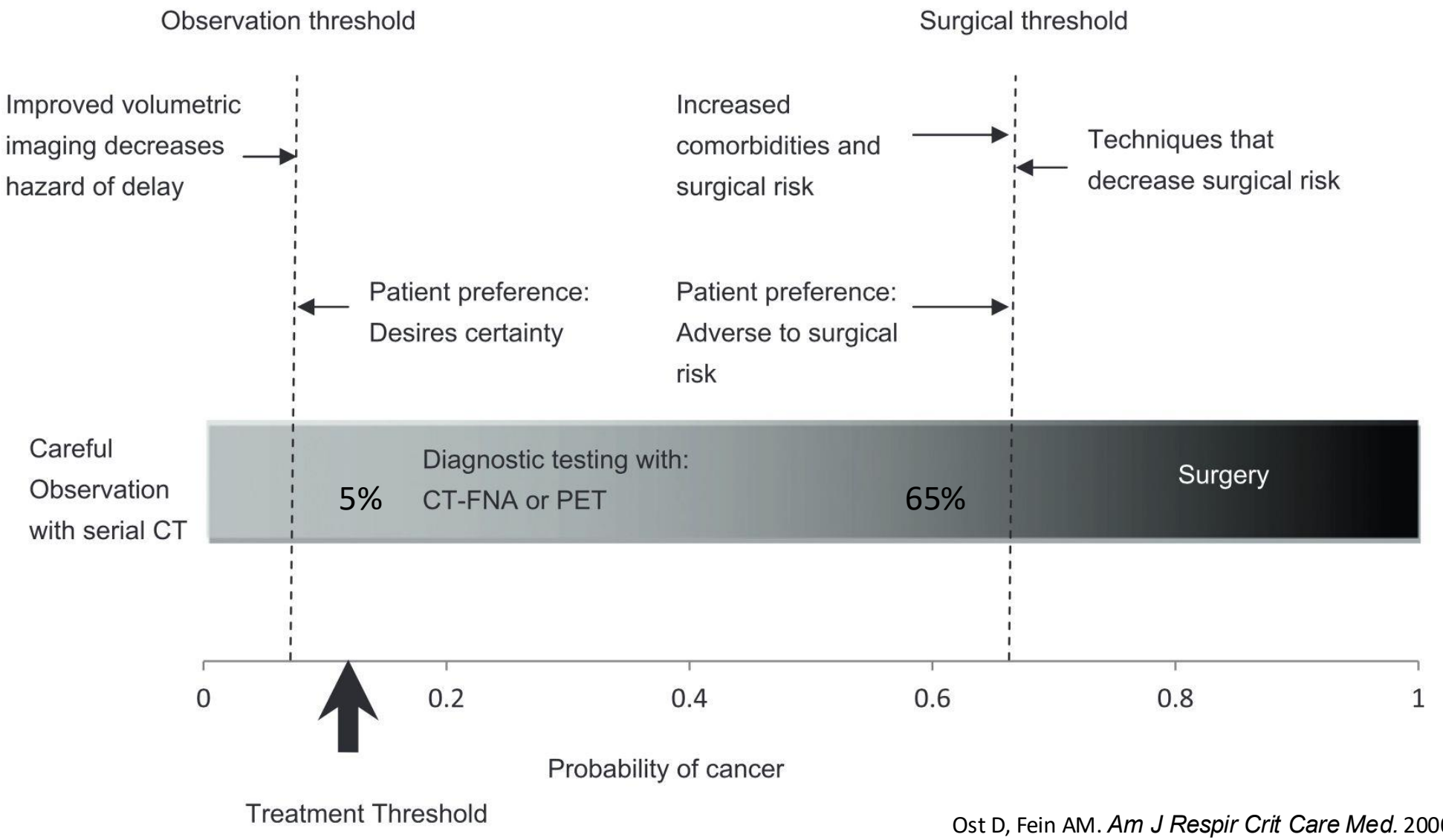

Ost D, Fein AM. *Am J Respir Crit Care Med.* 2000;162(3)

Lung Cancer Histology

PRIMARY LUNG CARCINOMA

SMALL CELL

High-grade neuroendocrine carcinoma

- Small cell lung carcinoma (SCLC)
- Combined SCLC

NON–SMALL CELL (NSCLC)

~85% of lung cancers

- Adenocarcinoma — most common
- Squamous cell carcinoma
- Large cell carcinoma
- Adenosquamous / sarcomatoid / others

OTHER NEUROENDOCRINE

Separate WHO neuroendocrine group

- Typical carcinoid
- Atypical carcinoid
- Large cell neuroendocrine carcinoma (LCNEC)

Reference: WHO Classification of Tumours Editorial Board. Thoracic Tumours. 5th ed. IARC; 2021. | Nicholson AG et al. J Thorac Oncol. 2022;17:362–387.

Lung Cancer Staging

- Correct staging is fundamental
- Guides treatment
- Infers prognosis

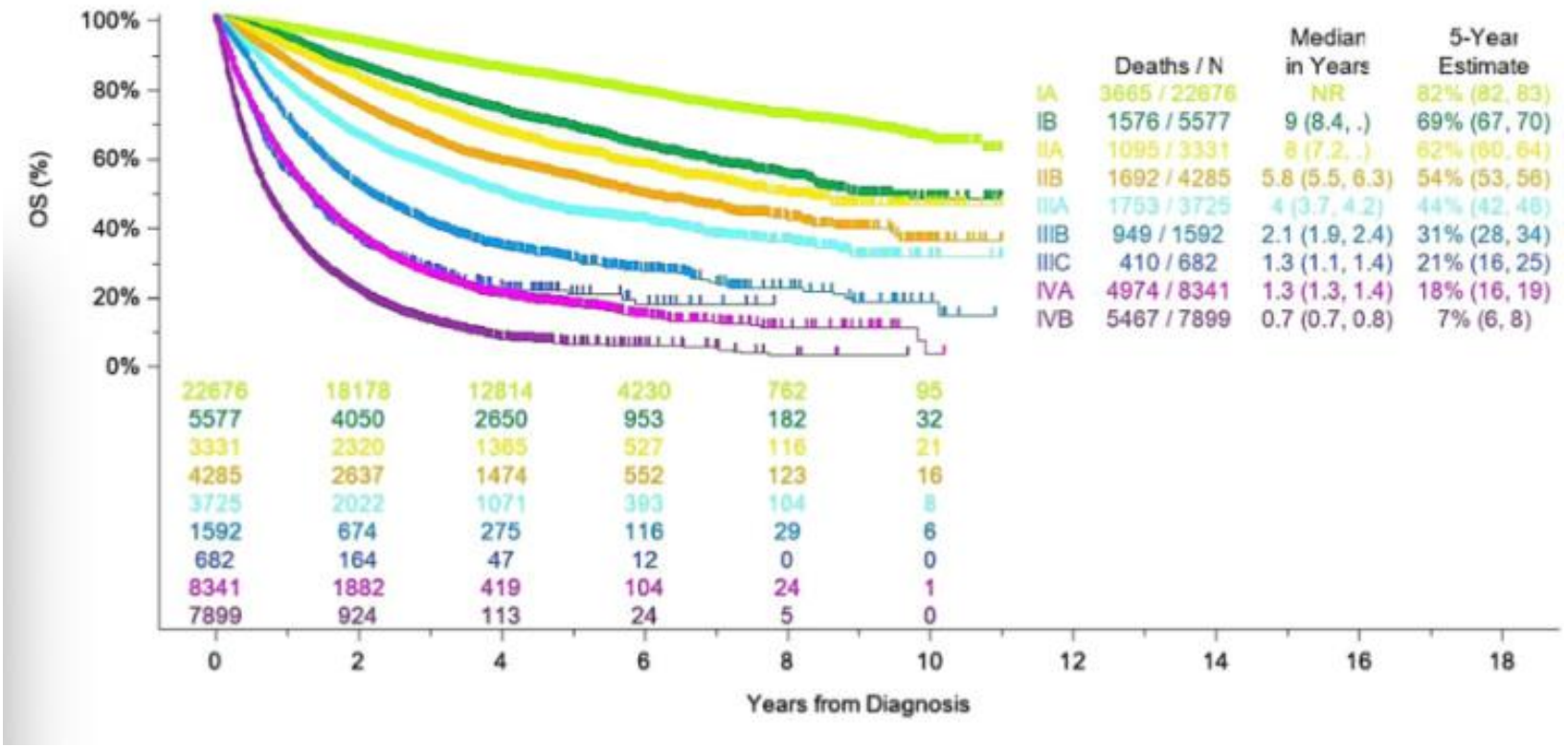

Rami-Porta, R., Nishimura, K. K., Giroux, D. J., et al. (2024). The International Association for the Study of Lung Cancer Lung Cancer Staging Project

Lung Cancer Staging

Non-small cell lung cancer

- TNM system
- IASLC (9th edition)

Proposed 9th Ed TNM Categories

T/M	Description	N0	N1	N2		N3
				N2a	**N2b**	
T1	T1a ≤1 cm	IA1	IIA	IIB	IIIA	IIIB
	T1b >1 to ≤2 cm	IA2	IIA	IIB	IIIA	IIIB
	T1c >2 to ≤3 cm	IA3	IIA	IIB	IIIA	IIIB
T2	T2a Visceral pleura / central invasion	IB	IIB	IIIA	IIIB	IIIB
	T2a >3 to ≤4 cm	IB	IIB	IIIA	IIIB	IIIB
	T2b >4 to ≤5 cm	IIA	IIB	IIIA	IIIB	IIIB
T3	T3 >5 to ≤7 cm	IIB	IIIA	IIIA	IIIB	IIIC
	T3 Invasion	IIB	IIIA	IIIA	IIIB	IIIC
	T3 Same lobe tumor nodule	IIB	IIIA	IIIA	IIIB	IIIC
T4	T4 >7 cm	IIIA	IIIA	IIIB	IIIB	IIIC
	T4 Invasion	IIIA	IIIA	IIIB	IIIB	IIIC
	T4 Ipsilateral tumor nodule	IIIA	IIIA	IIIB	IIIB	IIIC
M1	M1a Pleural / pericardial dissemination	IVA	IVA	IVA	IVA	IVA
	M1a Contralateral tumor nodule	IVA	IVA	IVA	IVA	IVA
	M1b Single extrathoracic lesion	IVA	IVA	IVA	IVA	IVA
	M1c1 Multiple lesions, 1 organ system	IVB	IVB	IVB	IVB	IVB
	M1c2 Multiple lesions, >1 organ system	IVB	IVB	IVB	IVB	IVB

Small cell lung cancer

- Limited stage
- Extensive stage

T

IASLC

INTERNATIONAL ASSOCIATION FOR THE STUDY OF LUNG CANCER

Lung Cancer T Classification–9th Edition

T1a, T1b T1c

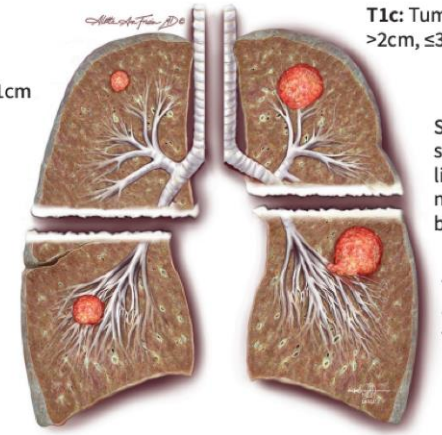

T1a: Tumor ≤1cm

T1b: Tumor >1cm, ≤2cm

T1c: Tumor >2cm, ≤3cm



Superficial spreading tumor of any size with its invasive component limited to the bronchial wall, which may extend proximal to the main bronchus, is T1

Tumor ≤3cm; without endobronchial extension proximal to the lobar bronchus

T2a T2b

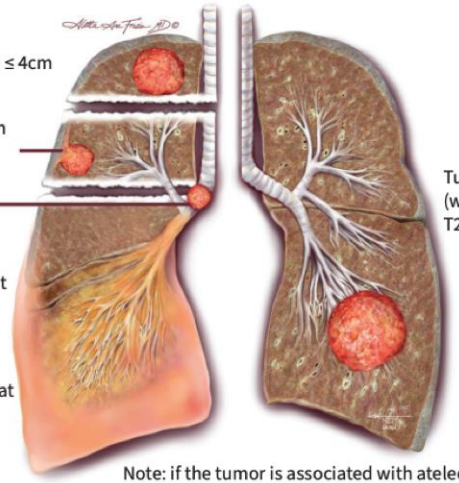

Tumor > 3cm, ≤ 4cm

Tumor ≤ 4cm, invasion of the visceral pleura

Tumor involves main bronchus, regardless of distance from carina but without carinal involvement

Associated atelectasis or obstructive pneumonitis that extends to the hilar region, either involving part of the lung or the entire lung

Tumor > 4cm, ≤ 5cm (with or without other T2 descriptors)

Note: if the tumor is associated with atelectasis or pneumonitis, it is T2a if lesion ≤ 4cm or if tumor size cannot be measured; it is T2b if lesion > 4cm, ≤ 5cm.

Figure Courtesy of International Association for the Study of Lung Cancer. Permission must be requested and granted before

IASLC

INTERNATIONAL ASSOCIATION FOR THE STUDY OF LUNG CANCER

Lung Cancer T Classification–9th Edition

T3

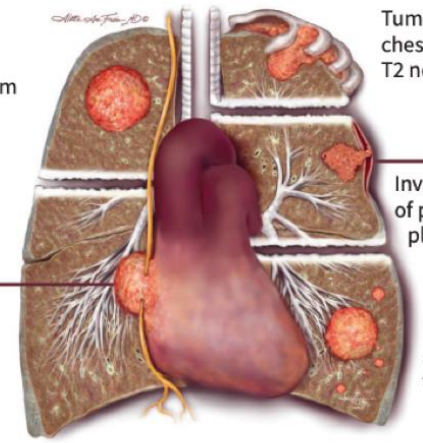

Tumor > 5cm, ≤ 7cm

Tumor invades parietal pleura or chest wall or invades thoracic T1, T2 nerve roots, or stellate ganglion

Invasion of the azygos vein, phrenic nerve, or pericardium

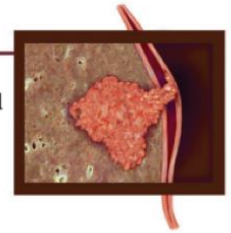

Invasion of parietal pleura

Separate tumor nodule(s) in the lobe of the primary

T4

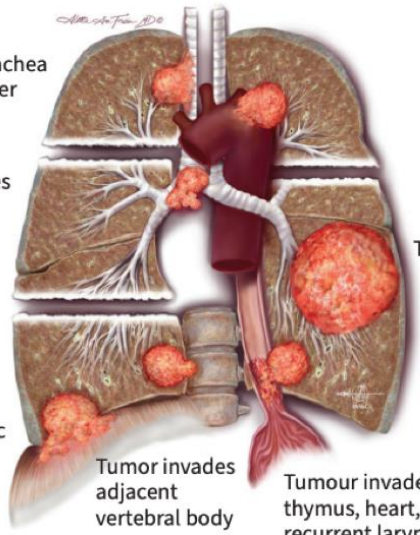

Tumor invades trachea and/or SVC or other great vessel

Tumor involves carina

Diaphragmatic invasion

Tumor invades adjacent vertebral body

Tumour invades mediastinum, thymus, heart, vagus nerve, recurrent laryngeal nerve, esophagus or diaphragm



Tumor that invades subclavian vessels, vertebral body, lamina, spinal canal, cervical nerve roots, or brachial plexus

Tumor > 7cm

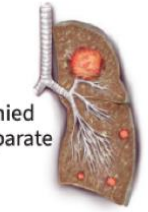

Tumor accompanied by ipsilateral, separate tumor nodules, different lobe

N

N0

No regional lymph node metastases

N1

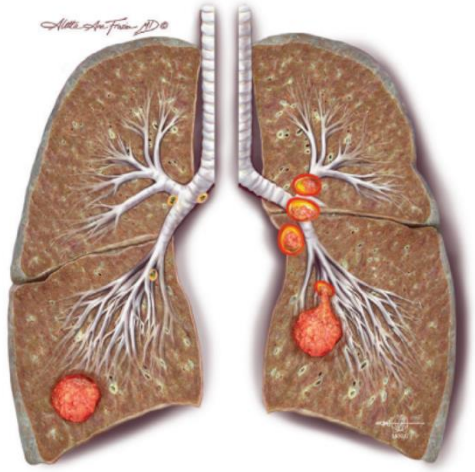

Metastasis in ipsilateral intrapulmonary/ peribronchial/ hilar lymph node(s) including nodal involvement by direct extension

N2a

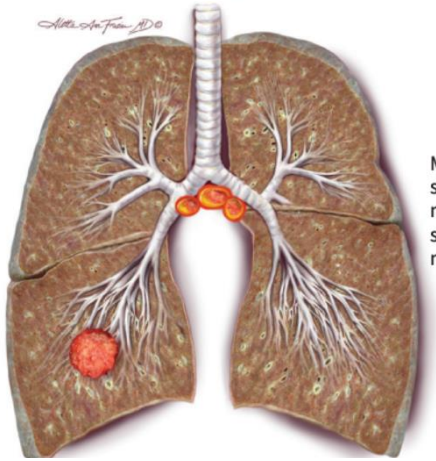

Metastasis to single ipsilateral mediastinal or subcarinal lymph node station

N2b

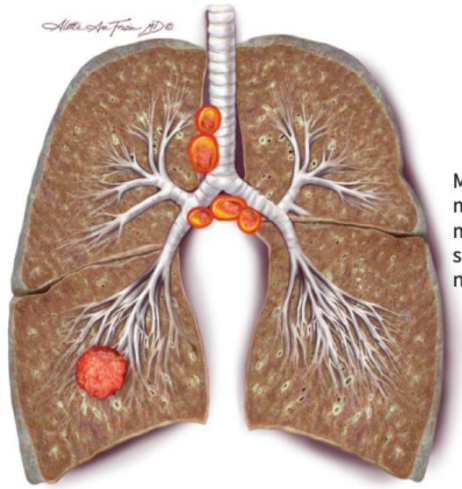

Metastasis to multiple ipsilateral mediastinal and/or subcarinal lymph node stations

N3

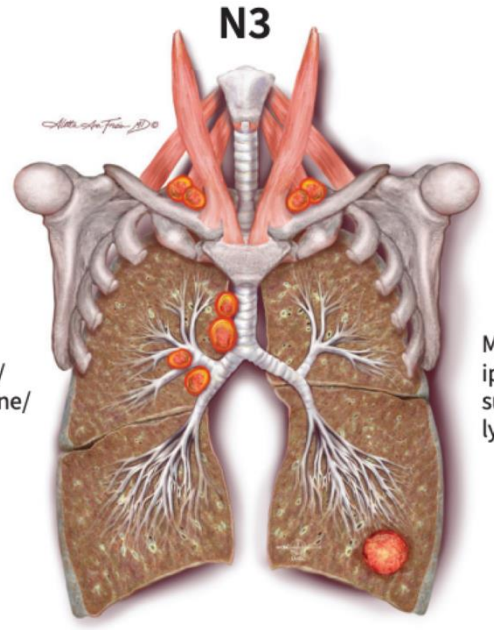

Metastasis in contralateral hilar/ mediastinal/scalene/ supraclavicular lymph node(s)

Metastasis in ipsilateral scalene/ supraclavicular lymph node(s)

M

M1a

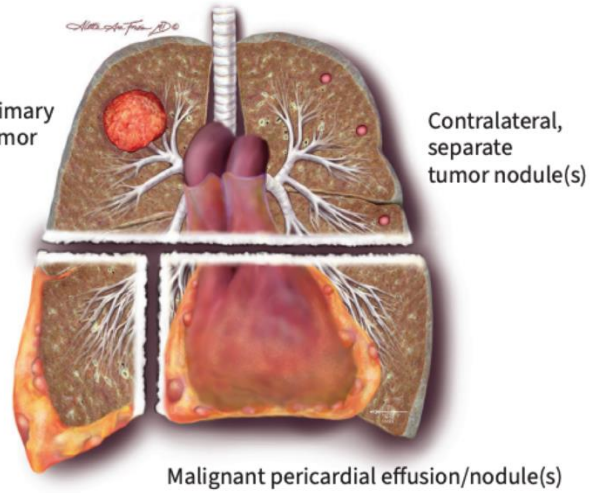

M1b

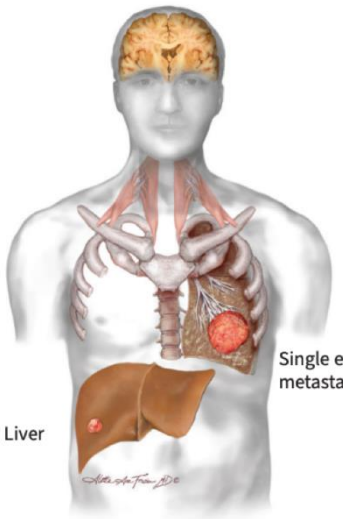

M1b

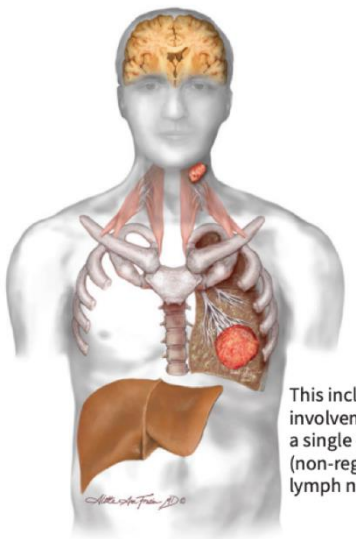

M1c1

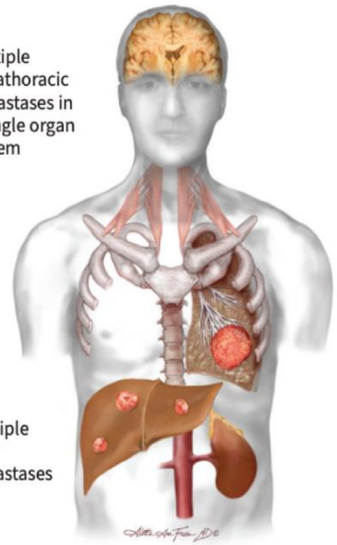

An organ system denotes all sites of an organ that is distributed in the body (e.g. the skeletal system, skin, extrathoracic lymphatic system) or of a paired organ (e.g. adrenal, kidney)

M1c2

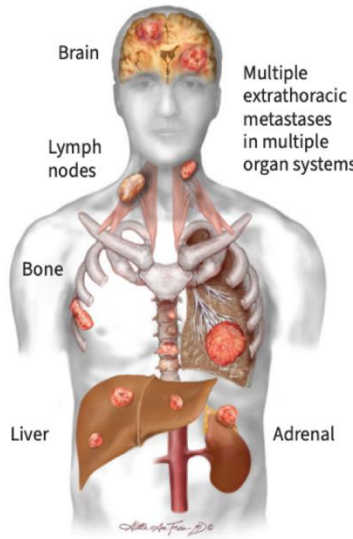

Fong KM, Rosenthal A, Giroux DJ, et al. The International Association for the Study of Lung Cancer staging project for lung cancer: Proposals for the revision of the M descriptors in the forthcoming ninth edition of the TNM classification of

Proposed 9th Ed TNM Categories

T/M	Description	N0	N1	N2		N3
				N2a	**N2b**	
T1	T1a ≤1 cm	IA1	IIA	IIB	IIIA	IIIB
	T1b >1 to ≤2 cm	IA2	IIA	IIB	IIIA	IIIB
	T1c >2 to ≤3 cm	IA3	IIA	IIB	IIIA	IIIB
T2	T2a Visceral pleura / central invasion	IB	IIB	IIIA	IIIB	IIIB
	T2a >3 to ≤4 cm	IB	IIB	IIIA	IIIB	IIIB
	T2b >4 to ≤5 cm	IIA	IIB	IIIA	IIIB	IIIB
T3	T3 >5 to ≤7 cm	IIB	IIIA	IIIA	IIIB	IIIC
	T3 Invasion	IIB	IIIA	IIIA	IIIB	IIIC
	T3 Same lobe tumor nodule	IIB	IIIA	IIIA	IIIB	IIIC
T4	T4 >7 cm	IIIA	IIIA	IIIB	IIIB	IIIC
	T4 Invasion	IIIA	IIIA	IIIB	IIIB	IIIC
	T4 Ipsilateral tumor nodule	IIIA	IIIA	IIIB	IIIB	IIIC
M1	M1a Pleural / pericardial dissemination	IVA	IVA	IVA	IVA	IVA
	M1a Contralateral tumor nodule	IVA	IVA	IVA	IVA	IVA
	M1b Single extrathoracic lesion	IVA	IVA	IVA	IVA	IVA
	M1c1 Multiple lesions, 1 organ system	IVB	IVB	IVB	IVB	IVB
	M1c2 Multiple lesions, >1 organ system	IVB	IVB	IVB	IVB	IVB

Rami-Porta, R., Nishimura, K. K., Giroux, D. J., et al. (2024). The International Association for the Study of Lung Cancer Lung Cancer Staging Project

Small Cell Lung Cancer staging

- **Limited Stage (30%)**
  - Can be encompassed in a single XRT port
- **Extensive Stage (70%)**
  - Clinically detectable distant metastases (M)
  - Tumor nodule/mass too large to include in a singe XRT port (T3,4)

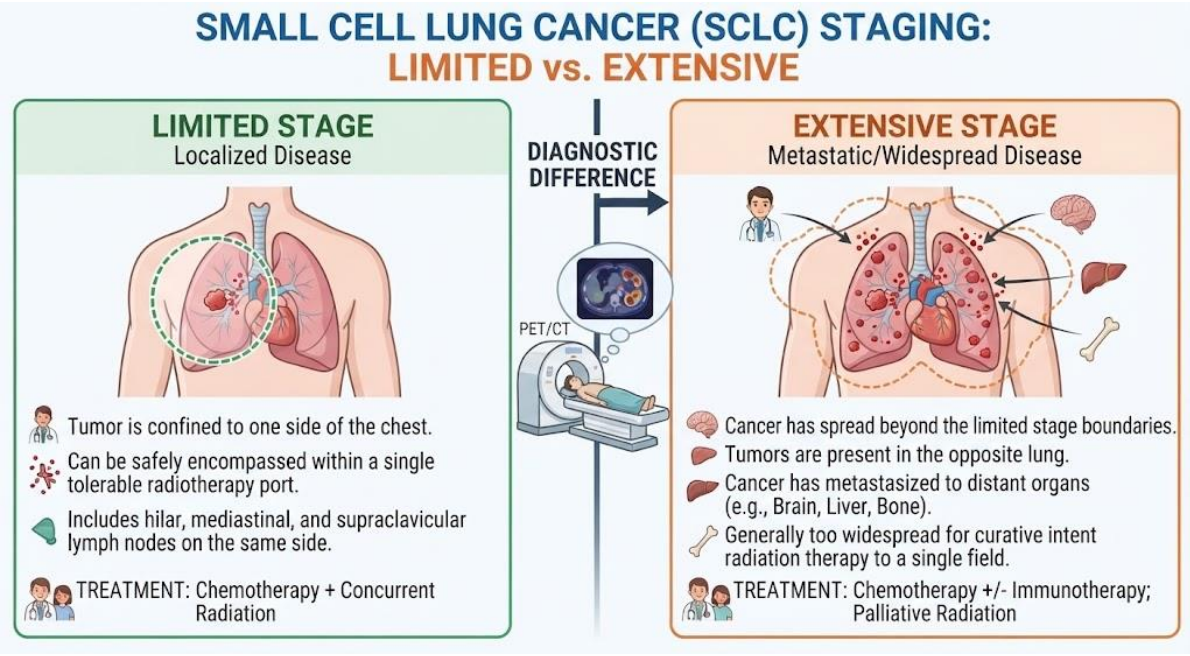

Lung Cancer Diagnostic workup

- **Timey diagnosis and staging**: < 6 weeks
- **Multidisciplinary approach**: pulmonary, thoracic surgery, medical oncology, radiation oncology, radiology, pathology
- **Tissue Sampling:**
  - Choice depends on lesion location + staging needs
  - Biopsy of site of disease representing highest stage
  - Ensure adequate tissue for diagnosis + molecular testing

Molecular Testing

- No longer optional
- Has treatment implications
  - **EGFR**
  - **ALK**
  - ROS1
  - BRAF
  - MET exon 14
  - RET
  - NTRK
  - KRAS G12C
  - **PD-L1**

Biopsy
CT guided TTNA

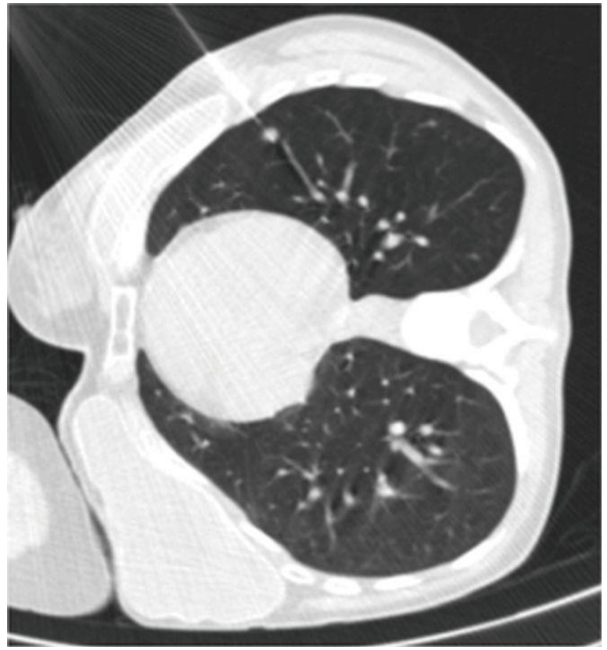

- Yield: Up to 90%
- Pneumothorax rate 25% - Chest tube 5%
- Hemorrhage ~ 2%

Highest yield and lowest complications:

- Lower distance from chest wall
- Larger Size
- No fissure in the way
- Lower number of passes
- Absence of emphysema

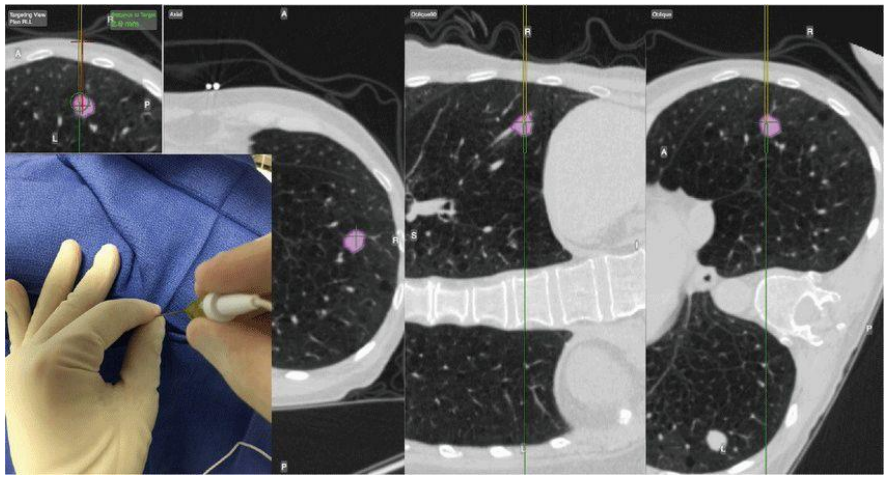

Biopsy
Bronchoscopic biopsy

- Endobronchial biopsy for central endobronchial tumors
- Fluoroscopic guided
  - Larger sizes higher yield
  - Overall yield low (30-60%)
  - 6-8 samples/bites
- Bronchus sign = higher yield
  - More proximal = higher yield

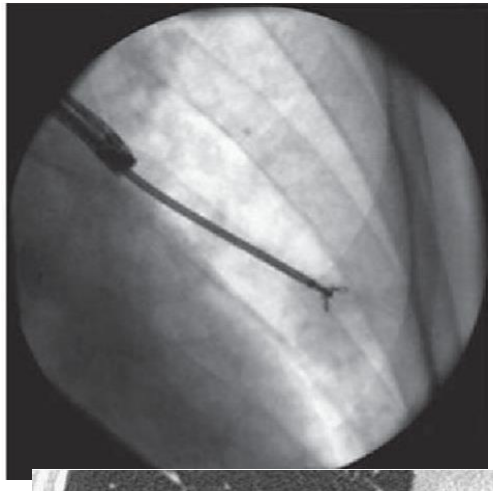



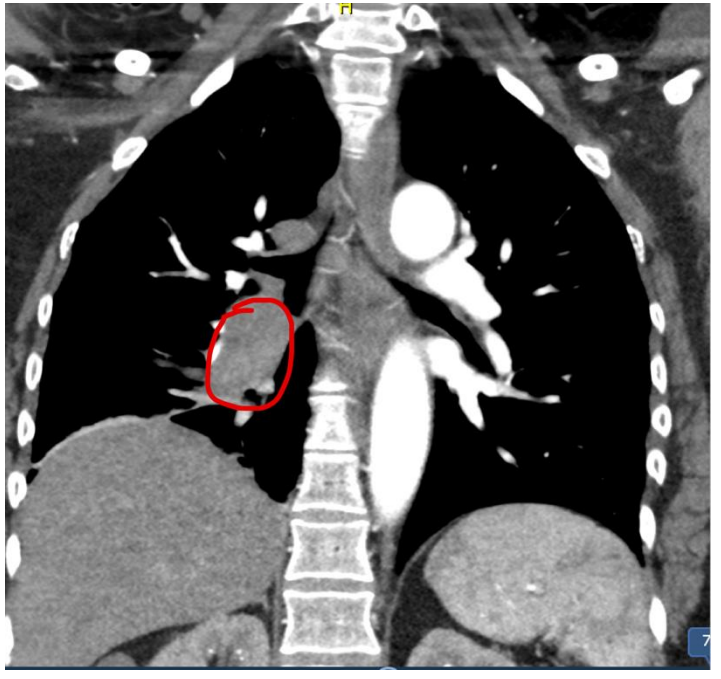

Bronchoscopic Biopsy
Radial EBUS



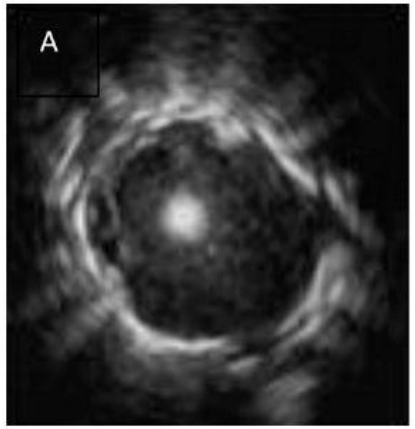

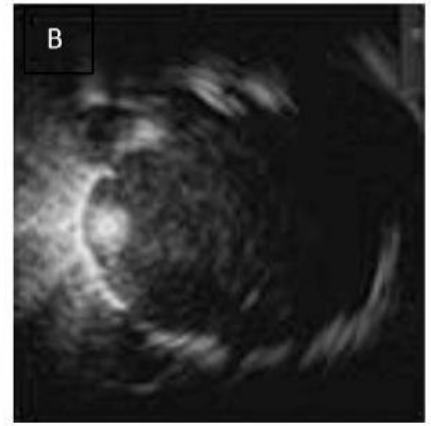

Concentric 84%

Eccentric 48%

	Yes	No
>2 cm	75.7%	60.5%
Malignant	72.4%	60.2%
Inside	78.7%	52.0%
Bronchus sign	76.5%	52.4%



- Ultra thin 74%
- Thin 59%

Bronchoscopic Biopsy
Electromagnetic Navigation Bronchoscopy

- Integrates VB with an electromagnetic field
- In patients with peripheral lung lesions
- Overall sensitivity 60-74%
- Falling out of favor due to rise of robotic bronchoscopy





Bronchoscopic Biopsy
Robotic Navigation Bronchoscopy

- Concurrent use of REBUS, fluoroscopy for real time sampling guidance
- Concurrent lymph node staging with EBUS
- Yield 80-95%
- Higher yield with 3D Fluoroscopy



3.2 Inner scope
2.0 working channel



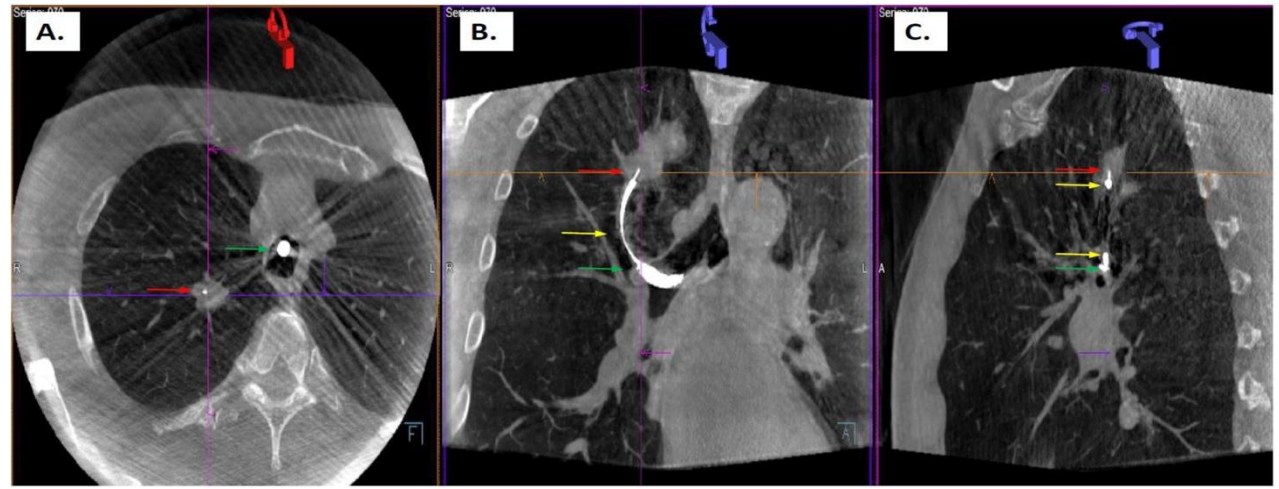

3D Fluoroscopy/cone beam CT
Tool-in-lesion image

Mediastinal staging

- Determines the N stage and the overall stage of lung cancer
- Should be done concurrently with other diagnostic testing if possible
- Imaging or invasive
  - EBUS TBNA
  - EUS
  - Mediastinoscopy
  - VATS

Mediastinal staging
Imaging

- Standard CT: (10mm LN size cutoff)
  - Sensitivity: ~55%
  - Specificity: ~80%
- FDG-PET: Using SUV > 2.5
  - Sensitivity: 65-80%
  - Specificity: 85-93%

Mediastinal staging
Invasive sampling indications

- Suspicion of N2,3 involvement on imaging
    - Lymph nodes > 1 cm
    - PET avid lymph nodes
- Tumors size > 3 cm
- Central tumors: in the middle or proximal third of the thorax
- Presence of N1 disease (Hilar lymph node positive or highly suspicious on imaging)

Mediastinal staging

Invasive sampling not necessary if:

- Peripheral < 3 cm tumors with negative nodal involvement by CT and PET
- Extensive tumors with clear infiltration to the mediastinum by CT and/or PET with proven and adequate tissue diagnosis
- Proven metastatic (M1) disease

Endobronchial Ultrasound (EBUS) Bronchoscopy

EBUS = first-line (ACCP)

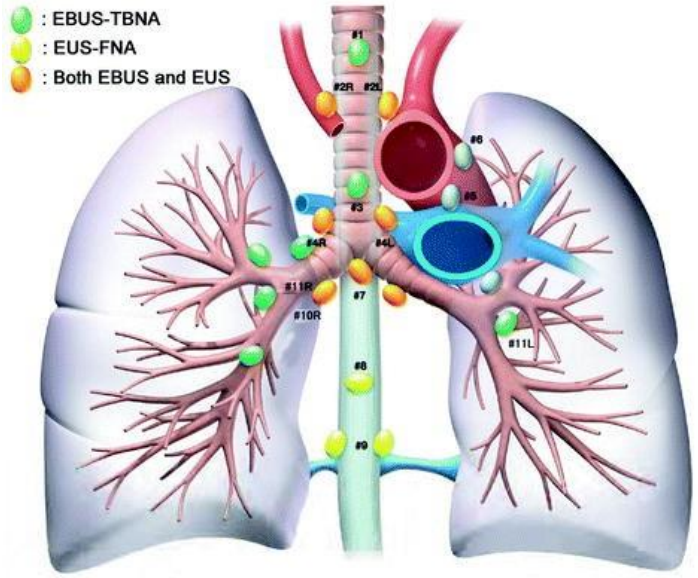

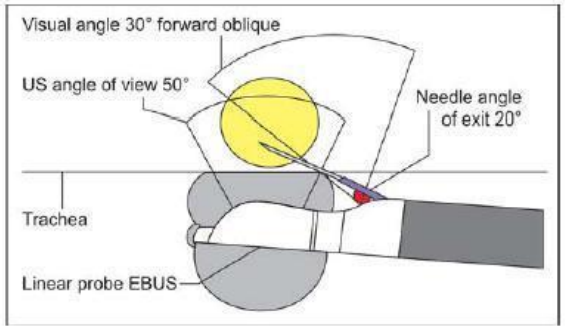

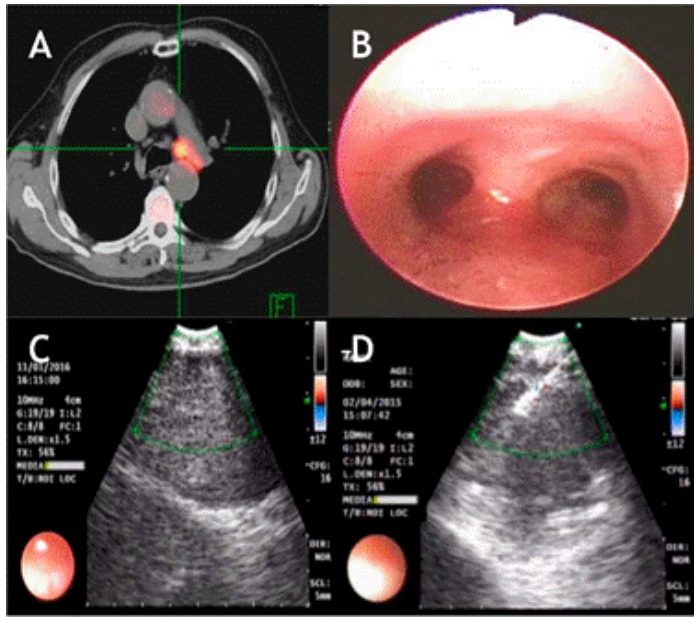

	Sensitivity
EBUS/TBNA	92%
EUS/FNA	89%
Combined	96%

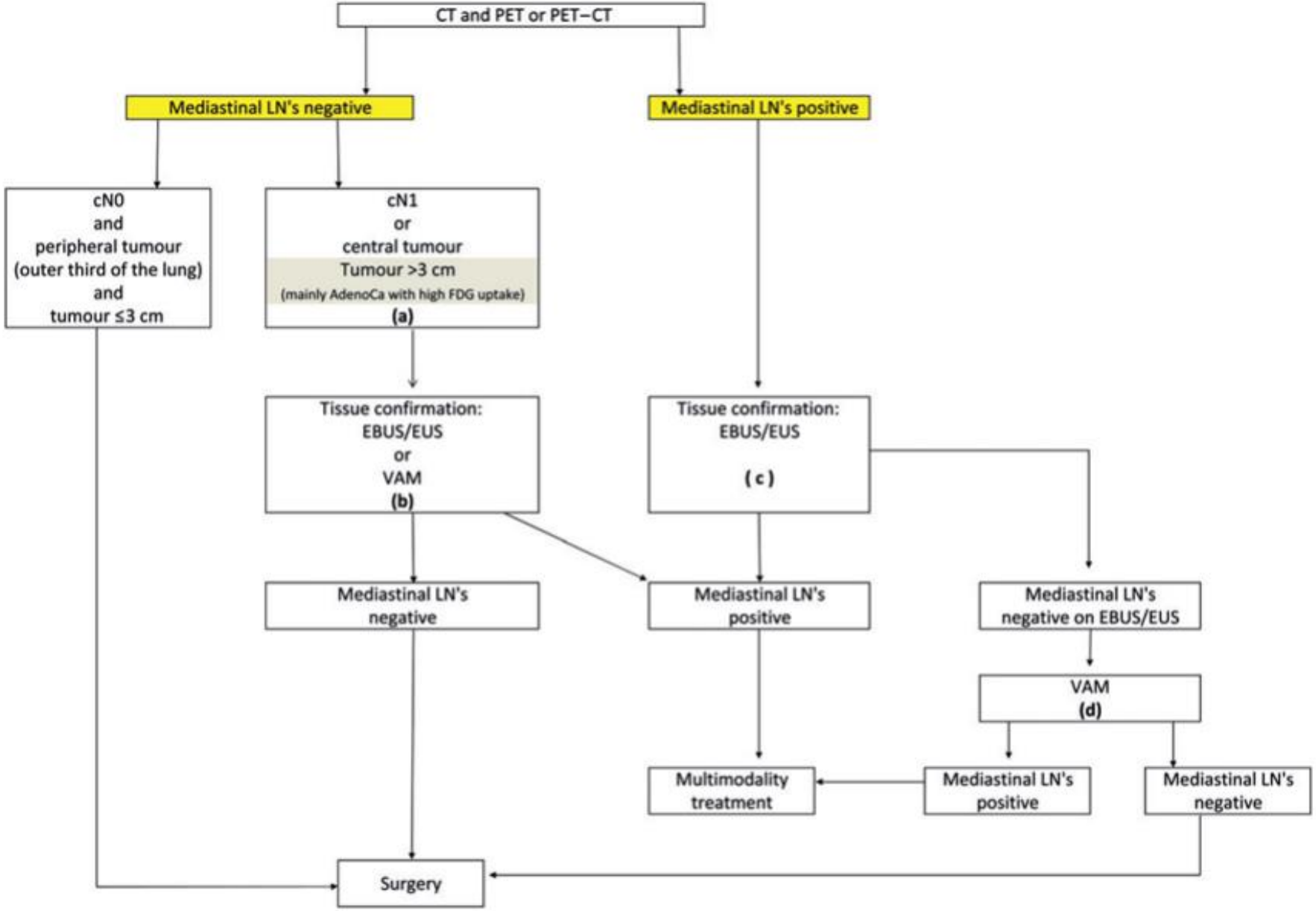

(a) : In tumours > 3 cm (mainly in adenocarcinoma with high FDG uptake) invasive staging should be considered
(b) : Depending on local expertise to adhere to minimal requirements for staging
(c) : Endoscopic techniques are minimally invasive and are the first choice if local expertise with EBUS/EUS needle aspiration is available
(d) : Due to its higher NPV, in case of PET positive or CT enlarged mediastinal LN's, videoassisted mediastinoscopy (VAM) with nodal dissection or biopsy remain indicated when endoscopic staging is negative. Nodal dissection has an increased accuracy over biopsy

Lung Cancer Treatment

Constantly evolving guidelines





NSC Lung Cancer Treatment
Overview

TNM Stage (8th Ed)	NCCN-Recommended Therapy (NSCLC)	5-year Survival (Approx.)
Stage IA1-IA2-IA3, IB	**Preferred:** Surgical resection (Lobectomy preferred). **Alternative/For high-risk patients:** Stereotactic Body Radiation Therapy (SBRT). **Stage IB:** Consider adjuvant chemotherapy for select high-risk cases (e.g., vascular **invasion, large tumors).**	**80% - 92%**
Stage IIA, IIB	**Preferred:** Surgical resection (Lobectomy) followed by adjuvant chemotherapy. **For medically inoperable patients:** Definitive Chemoradiotherapy (CRT).	**50% - 68%**
Stage IIIA, IIIB, IIIC (Locally Advanced)	**IIIA (e.g., T4N1, T1-2N2) and some IIIB (e.g., T3-4N2):** Multidisciplinary evaluation. **Often:** Concurrent Chemoradiotherapy (CRT) followed by Durvalumab consolidation. **Or:** Induction Chemotherapy -> Surgery (if resectable). **IIIB/IIIC (Unresectable, e.g., N3):** Definitive Concurrent Chemoradiotherapy.	**13% - 40%**
Stage IVA (M1a, M1b - oligometastatic), Stage IVB (M1c - widespread)	Systemic therapy is the foundation. Requires comprehensive molecular testing (EGFR, ALK, ROS1, BRAF, NTRK, MET, RET, PD-L1). If targetable mutation (e.g., EGFR+, ALK+): Corresponding targeted therapy (Tyrosine Kinase Inhibitor, TKI). If PD-L1 ≥ 50% (and no mutation): Pembrolizumab monotherapy or in combination with chemo. If PD-L1 1-49%: Chemo + Pembrolizumab/Ipilimumab combination. If PD-L1 < 1%: Chemotherapy + anti-PD-1/CTLA-4 inhibitor. Oligometastatic disease: Consider consolidative therapy (Surgery or SBRT) to primary and metastatic sites. Palliative care and symptom management integrated throughout.	**0% -25%**

NCCN

Therapy and survival are highly individualized based on patient performance status, comorbidities, and tumor histology/molecular profile. Consult the complete NCCN Guidelines for detailed information.

NSCLC Stage I Treatment
Surgery

- Lobectomy with mediastinal LN dissection
- VATS preferred over Thoracotomy
  - Less pain
  - Shorter hospital stays
  - Quicker return to function
  - Less morbidity
  - Improved compliance with adjuvant therapies
  - Cosmesis
- Sublobar resection acceptable
  - Poor cardiopulmonary reserve
  - Elderly population
  - Second primary tumors
  - Very small tumors

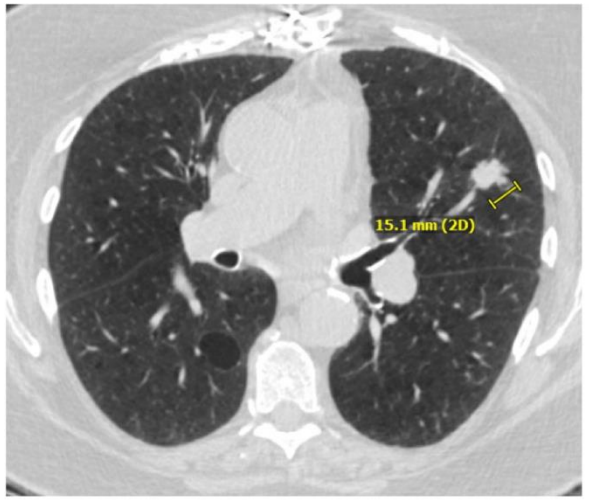

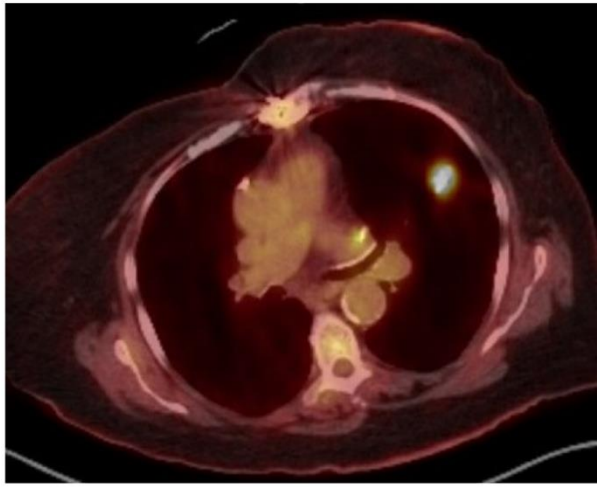

Pre-resection Assessment
Lung Function Testing

- Predicts/prevents morbidity and mortality from resection
- Calculate predictive post operative values: ppoFEV1 and ppo DLCO
- Ppo FEV1 = preFEV1 / $\frac{\text{(1- segments to be resected)}}{\text{total segments (19)}}$
- IF BOTH ppoFEV1 and ppoDLCO > 60% predicted → no more testing needed
- If EITHER ppoFEV1 and ppoDLCO is < 60% but > 30% → additional physiologic assessment: shuttle walk or stair climb
- If EITHER ppoFEV1 and ppoDLCO is < 30 % → CPET

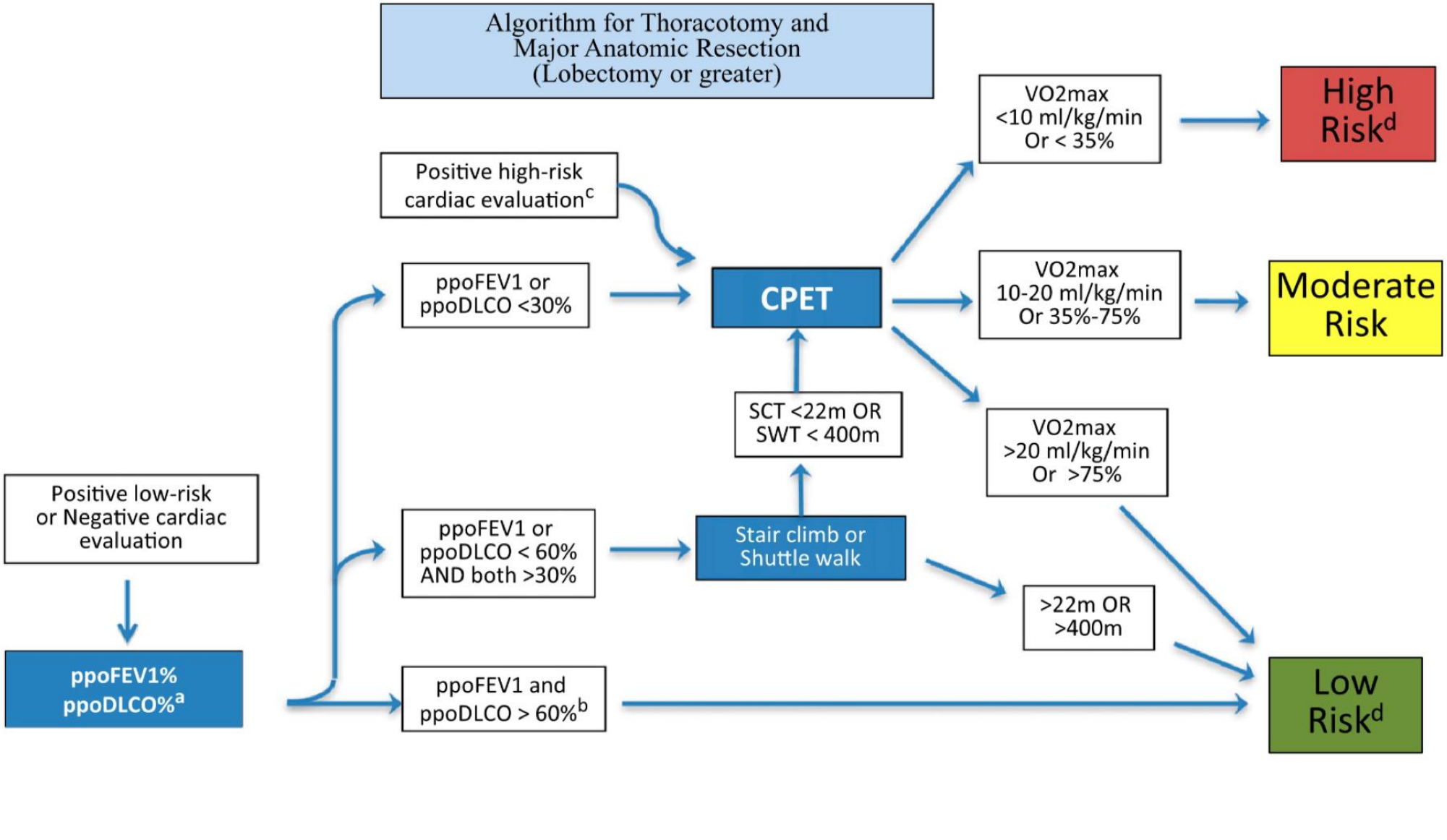

Brunelli, A., et al. Physiologic evaluation of the patient with lung cancer being considered for resection. American College of Chest Physicians evidence-based clinical practice guidelines. *Chest*, *143*(5 Suppl), e166S–e190S.

NSC Lung Cancer Stage I Treatment
Radiation

Stereotactic Body Radiotherapy (SBRT)

- For non-surgical candidates
- Steep dose-gradients
- Hypofractionation (3-8 sessions)
- High biological effective dose

- Indications
  - High risk surgical patients
  - Refusal of surgery

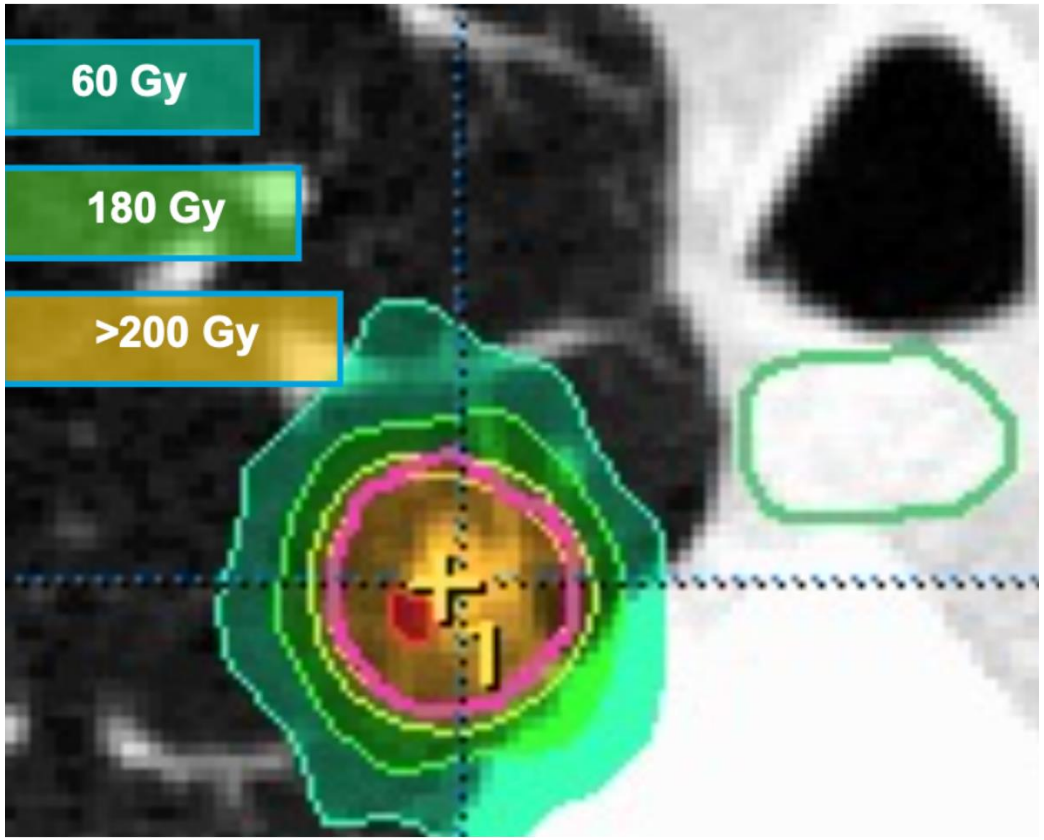

NSC Lung Cancer Stage I treatment
Adjuvant therapy

- Not routinely recommended
- Only indicated for tumors with high-risk features:
  - Tumor >4 cm
  - Poor differentiation
  - Visceral pleural invasion
  - Lympho-vascular invasion
  - Sublobar/wedge resection
  - Unknown/inadequate nodal evaluation (Nx)

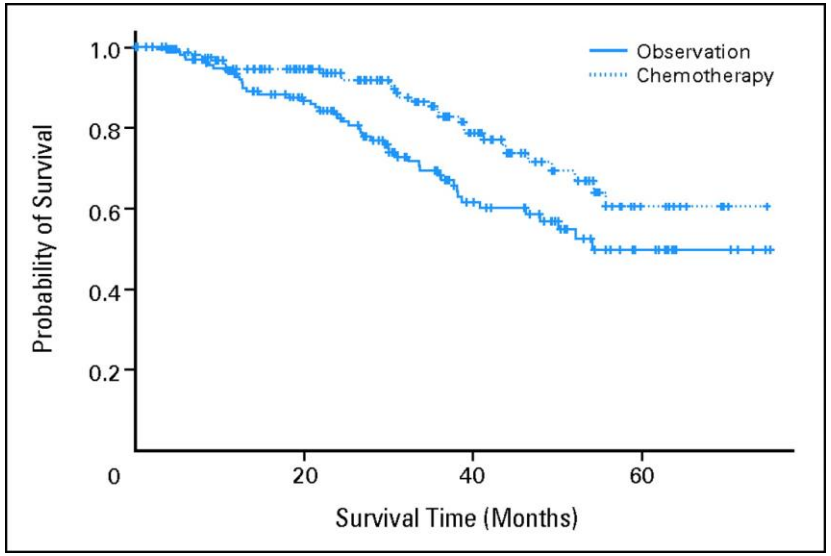

- Carboplatin-based (CALGB 9633 trial)
- Osimertinib in EGFR-mutated tumors (ARDURA trial)

CALGB 9633: benefit ONLY for tumors = or> 4 cm

Other stage IB adjuvant chemotherapy trials

COMPARISON OF KEY ADJUVANT CHEMOTHERAPY TRIALS IN NON-SMALL-CELL LUNG CANCER (NSCLC)

Trial Name	Patient Stage	Chemotherapy Used	Main Outcome
CALGB 9633	Stage: IB exclusively	Paclitaxel + Carboplatin	**Negative** (Benefit only for ≥ 4 cm tumors)
IALT	I, II, III	Cisplatin-based	**Positive** initially; benefit faded with long-term follow-up
JBR.10	IB, II	Cisplatin + Vinorelbine	**Positive** (Benefit restricted to stage II)
ANITA	IB, II, IIIA	Cisplatin + Vinorelbine	**Positive** overall; no benefit found for stage IB subset

NSC Lung Cancer Stage II Treatment

- Surgery plus Adjuvant Chemotherapy
- Adding adjuvant chemotherapy increased 5-year survival by 5.4%
  - Vinorelbine, Etoposide, Vinca alkaloids, others
  - Adjuvant Osimertinib for EGFR-mutated tumors
- Rationale of adjuvant therapy:
  - 5-year survival 50-70%
  - 2/3rds of relapses occur distally and 1/3 locally

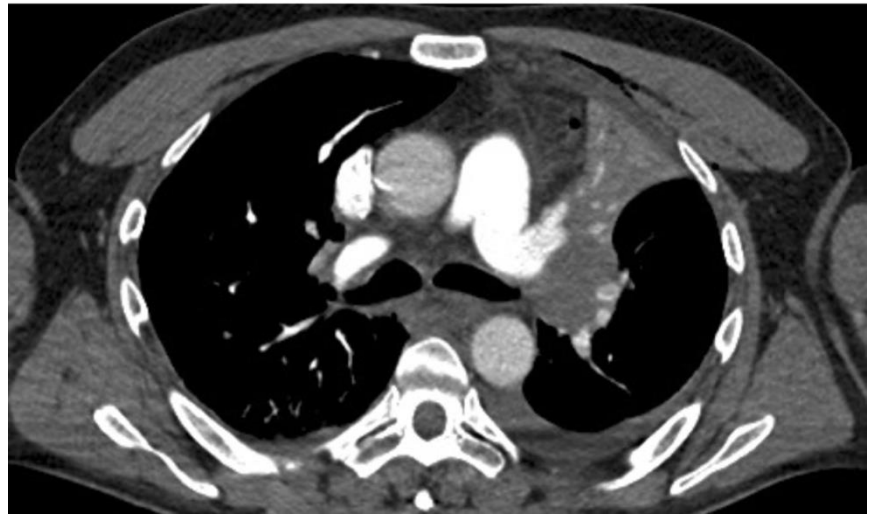

•Jean-Pierre Pignon et al. Lung Adjuvant Cisplatin Evaluation: A Pooled Analysis by the LACE Collaborative Group. *J Clin Oncol* **26**, 3552-3559(2008).

Pancoast (Sup Sulcus)Tumor

- Apex of the lung
- May invade contiguous structures → local pain
- May involve brachial plexus → radiating pain to the arm
- Horner's syndrome:
  - Sympathetic chain and stellate ganglion
  - Unilateral enopthalmos, ptosis, meiosis, ipsilateral anhydrosis
- Treatment
  - Resectable: induction chemoradiotherapy followed by En bloc resection
  - Non-resectable: Chemoradiotherapy

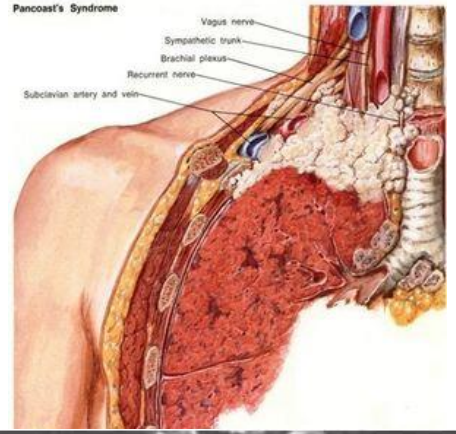



Stage I and II NCCLC
follow up and surveillance

- H&P + CT every 6 months for 2 years then yearly until 5 yrs
- If still eligible for LCS afterwords → yearly LDCT
- Second primaries are common:
  - Treatment is no different from initial
  - Outcome is poorer

Stage III NSCLC Treatment

- Multi-disciplinary
- Resectable (mostly IIIA):
  - Neoadjuvant chemo + Immunotherapy (Nivolomab) → Resection → Post-operative immunotherapy
- Non-Resectable (mostly IIIB)
  - Concurrent Chemotherapy + Radiation therapy → consolidative immunotherapy based on biomarkers
- Targeted therapy: if EGFR (Osimertinib) or ALK (Alectinib) mutations +ive

[Authors/CheckMate 816 Investigators]. Overall Survival with Neoadjuvant Nivolumab plus Chemotherapy in Lung Cancer. *N Engl J Med*. 2025;393(8):741-752.

Antonia SJ, Villegas A, Daniel D, et al. Overall Survival with Durvalumab after Chemoradiotherapy in Stage III NSCLC. *N Engl J Med*. 2018;379(24):2342-2350. (PACIFIC TRIAL)

Stage IV NSCLC treatment

1. Test before treating

- Broad molecular profiling + PD-L1
- At minimum EGFR, ALK, ROS1, BRAF V600E, MET exon14, RET, NTRK, KRAS G12C, HER2

2. Actionable driver present

- Use the preferred matched targeted therapy when available.
- PD-L1 level does NOT override an actionable oncogenic driver.

3. No actionable driver

- Chemotherapy + Immunotherapy: based on histology, PD-L1, performance status
- PD-L1 ≥50% may allow single-agent checkpoint inhibitor

Chemotherapy in NSCLC

- Platinum based
  - cisplatin and etoposide
  - carboplatin and pemetrexed
  - carboplatin and paclitaxel
- Given in cycles, with a period of treatment followed by a break for recovery.
- 4-6 cycles
- Advanced NSCLC may require longer treatment or until the disease becomes resistant to the chemotherapy.
- Treatment decisions are tailored to each patient, considering factors like cancer stage, type, gene mutations, and overall health

Targeted therapy in NSCLC

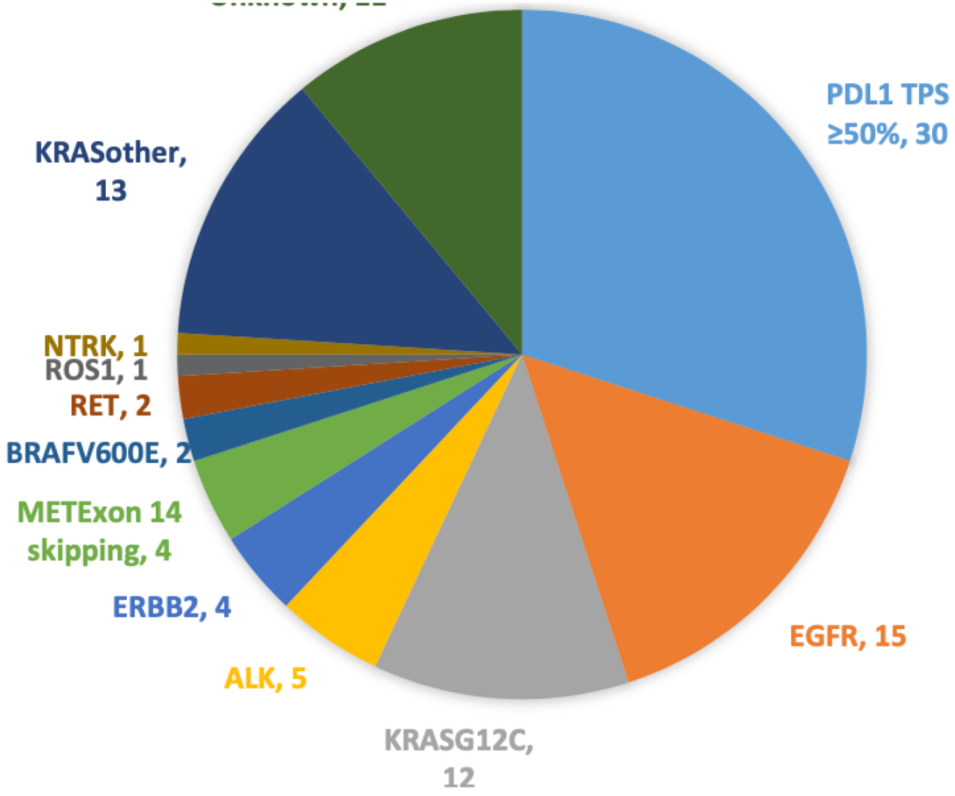

2020: biomarkers with drug targets

Target	Prevalence	Initial FDA Approval	Drugs
EGFR	10-15%	2003	Gefitinib, Erlotinib, Afatinib, Osimertinib,
ALK	2-7%	2011	Crizotinib, Ceritinib, Alectinib, Lorlatinib, Brigantinib,
R0S-1	1-2%	2016	Crizotinib, Entrectinib, Ceritinib, Lorlatinib
PD-L1 TPS 50%	30%	2016	Pembrolizumab, Atezolizumab
B-RAF^{V600E}	2%	2017	Dabrafenib+Trametinib, Vemurafenib
NTRK	0.2-3%	2018	Larotrectinib, Entrectinib
HER-2 (ERBB2)	2-5%	May 2020	Trastuzumab deruxtecan (Enhertu)
MET $^{\text{exon 14 skipping}}$	3-4%	May 2020	Capmatinib; ?Tepotinib?, Crizotinib
RET	1-2%	September 4, 2020	Salpercatinib, Pralsetinib, Carbozantinib, Vandetanib
K-RAS ^{G12C}	12%	2021	sotorasib

EGFR mutation

- Clinical factors that predict response:
  - **Adenocarcinoma**
  - **Never smokers**
  - **Females**
  - **East Asian heritage**

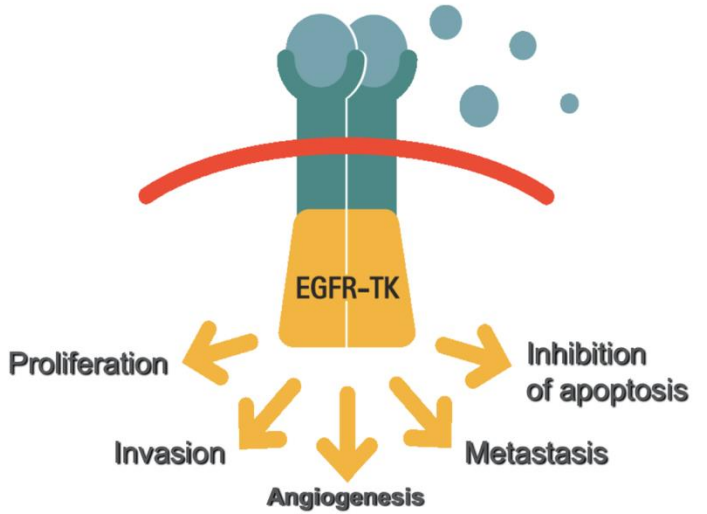

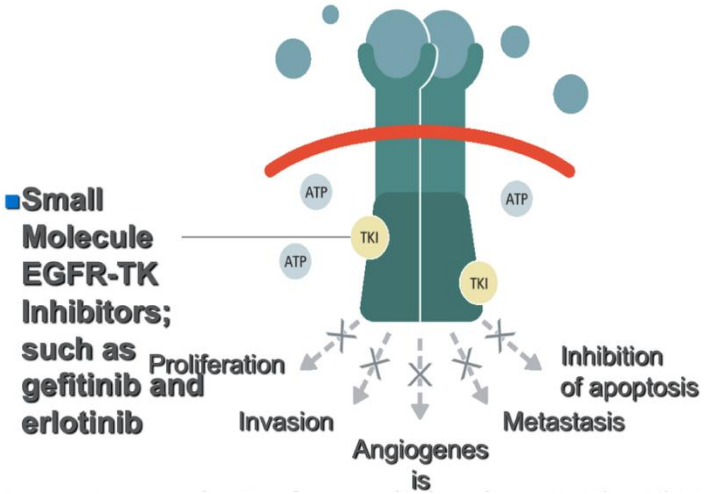

Immunotherapy in NSCLC (Immune checkpoint inhibitors)

- Signaling from dendritic cells or tumor cells can down-regulate T-cell activity
- Blockade of inhibitory signaling molecules on T- cells “re-activates” their anti-tumoral activity.

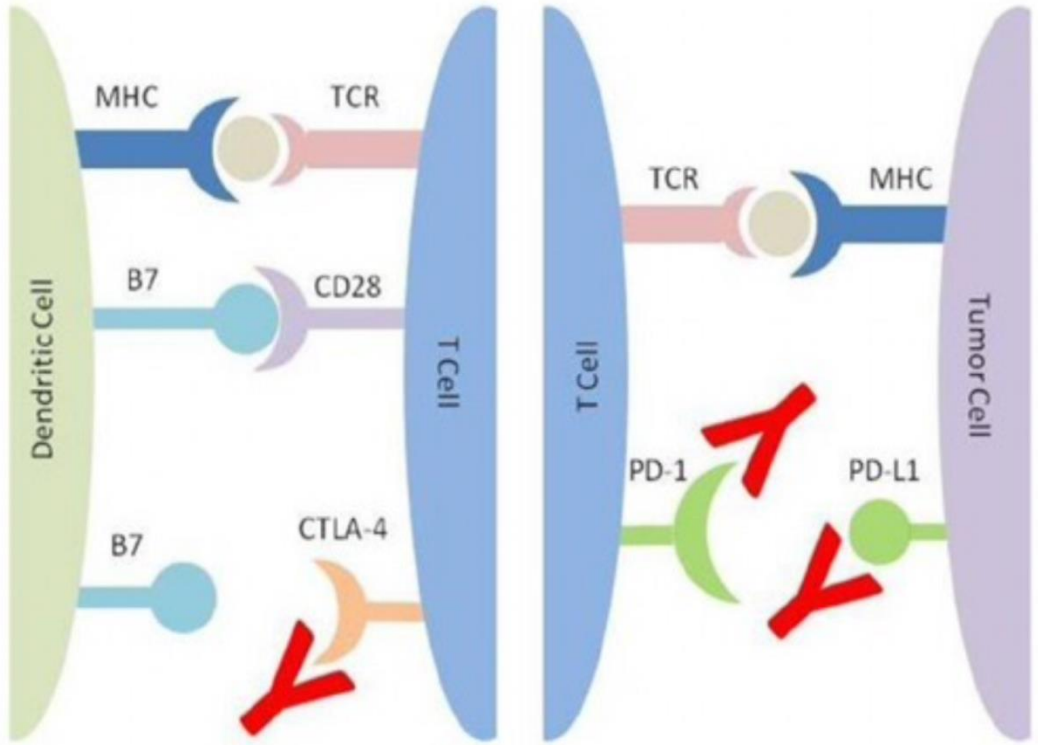

PDL-1 Inhibitors
Anti-PD-L1 antibodies

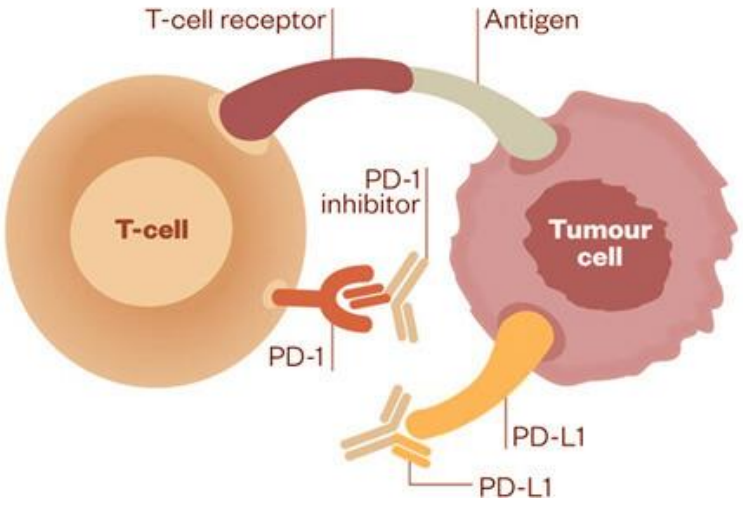

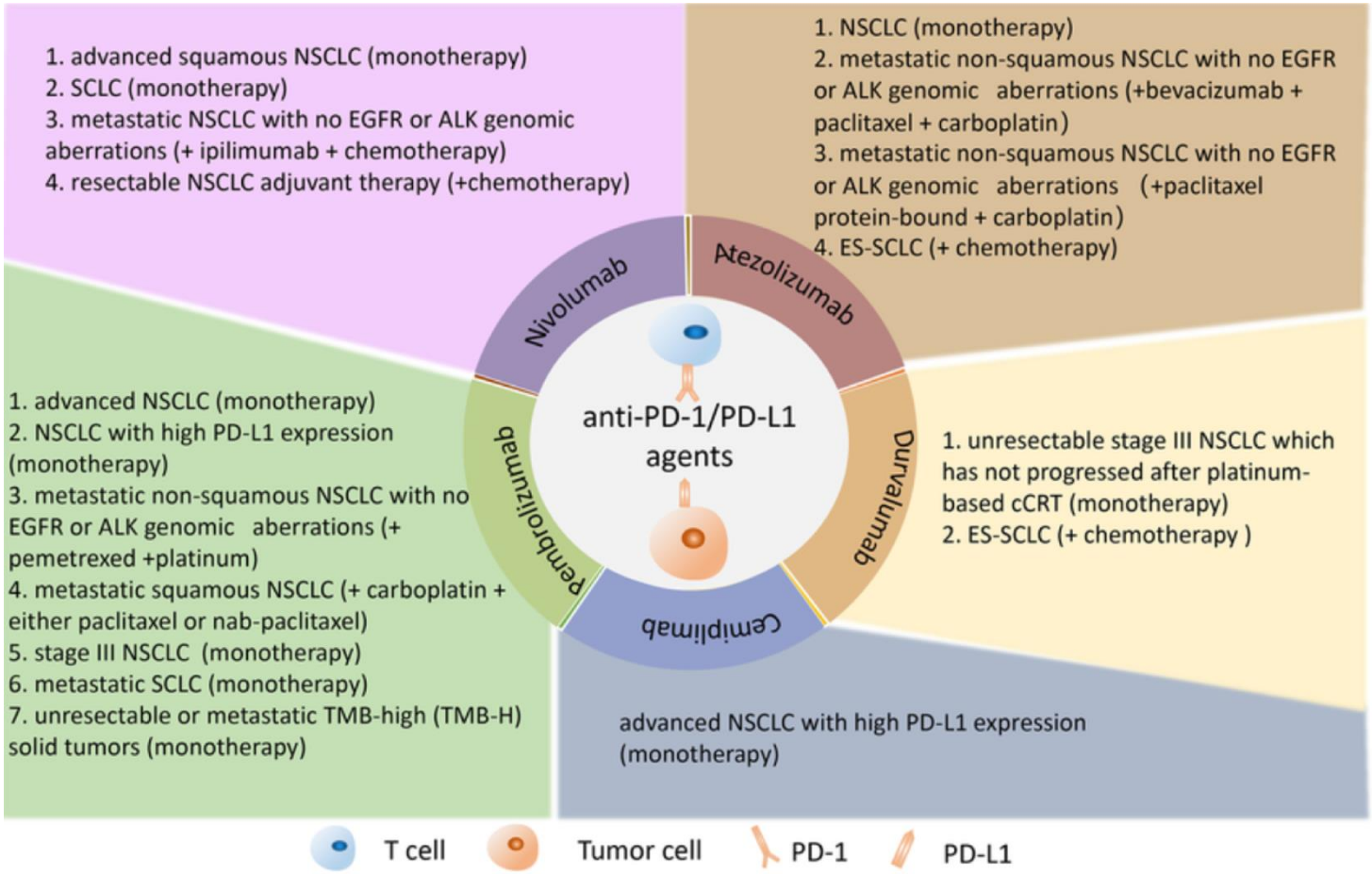

PDL- 1 Inhibitors
Immune-related adverse events

- Pneumonitis
  - Grade 1: Asymptomatic with radiographic changes
    - Continue therapy with close observation
  - Grade 2: Symptomatic but no limitation of usual activity
    - Hold therapy, consider bronchoscopy, start oral prednisone 1 mg/kg/day if no improvement
  - Grade 3: Symptomatic, with oxygen requirement or limitation of activity
  - Grade 4: Severe or life-threatening
    - For grades 3-4 Discontinue therapy, bronchoscopy, institute oral prednisone 1-2 mg/kg/day or IV corticosteroids at equivalent dose

Organ System	Common Side Effects	Severe Complications
Pulmonary	Mild cough, dyspnea	Immune-mediated pneumonitis
Gastrointestinal	Diarrhea, mild nausea	Severe colitis, bowel perforation
Endocrine	Fatigue, mild weakness	Hypophysitis, thyroiditis, type 1 diabetes
Dermatologic	Pruritus, mild rash	Severe bullous dermatitis, TEN / SJS
Hepatic & Other	Mild transaminitis, arthralgia	Hepatitis, myocarditis, nephritis

Management: Early recognition, prompt corticosteroid initiation, and multidisciplinary toxicity intervention. NCCN Guidelines

Treatment of Small Cell Lung Cancer

Limited Stage

Curative intent

Concurrent platinum + etoposide + thoracic RT

↓

If no progression: durvalumab consolidation up to 2 years

Extensive Stage

Platinum + etoposide + PD-L1 inhibitor

↓

Maintenance immunotherapy

↓

At progression: subsequent-line therapy

Prophylactic Cranial Irradiation in SCLC

- SCLC patients have 60% chance of developing CNS mets within 2-3 yrs
- PCI decreases chance of CNS mets by 50%
- Adds a small survival benefit and QOL benefit

Lung cancer prevention

- Smoking cessation is key
- Within 5 years: The risk of lung cancer in former heavy smokers drops by 39% compared to current smokers
- Within 10 years: The risk of lung cancer is about half that of a person who is still smoking.

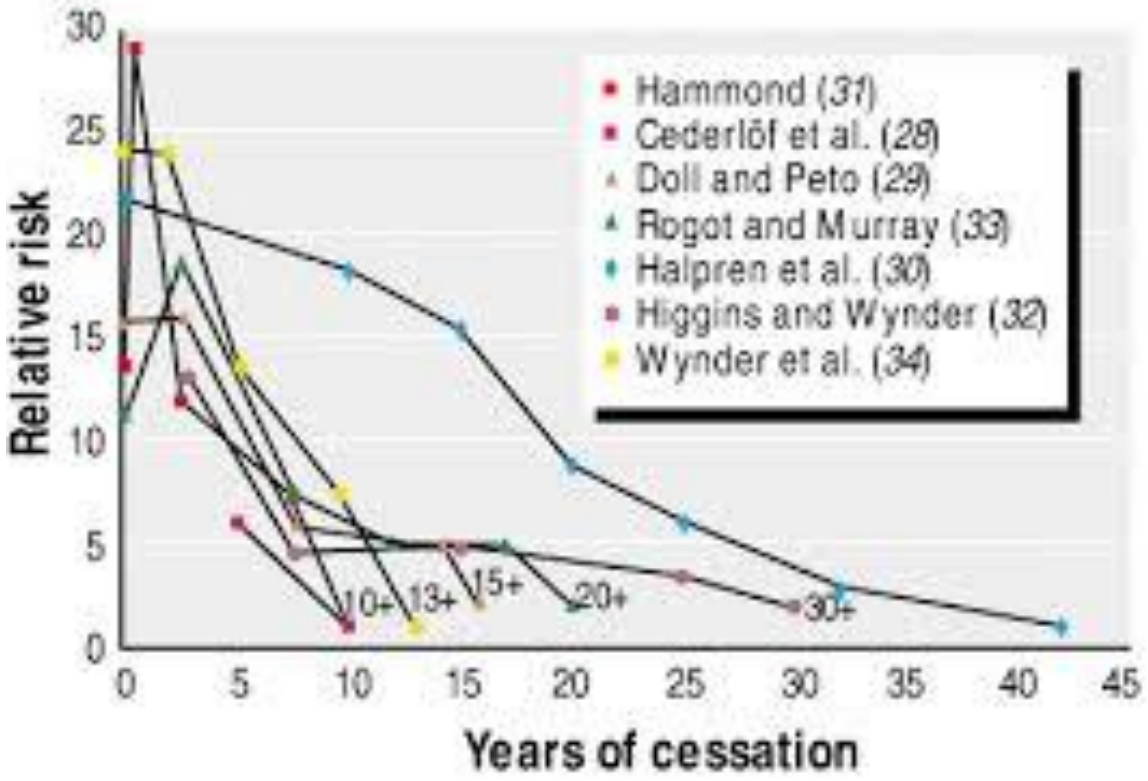

Early detection and screening of Lung Cancer

Stage Distribution (%) of New Cancer Cases, All Ages, All Races and Ethnicities, Both Sexes
Lung and Bronchus, United States, 2015-2019

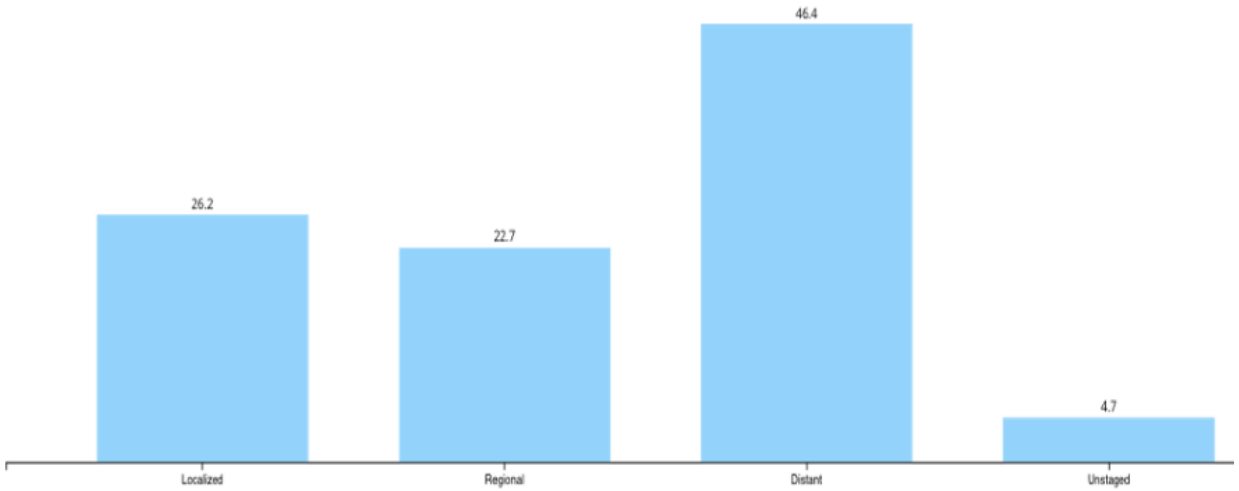

5-Year Relative Survival (%) by Stage Distribution of Cancer Cases, All Ages, All Races and Ethnicities, Both Sexes
Lung and Bronchus, United States, 2015-2019

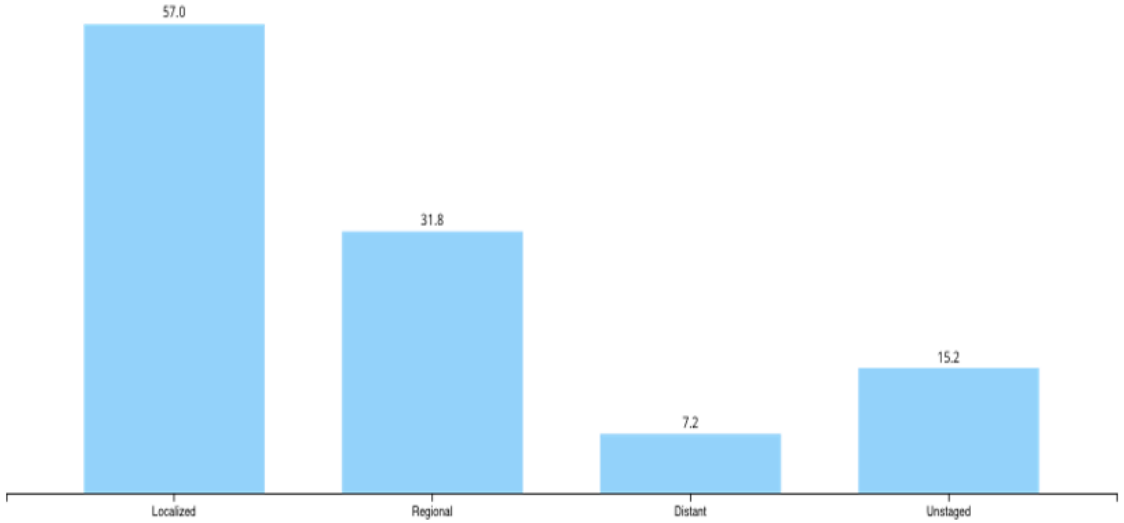

Lung cancer screening

- Yearly low dose CT chest
- Criteria
  - Age 50-80 years old
  - 20 pack-year smoking
  - Still smoking or quit smoking less than 15 years ago
- Benefits:
  - 15% to 20% lower lung cancer deaths
  - 6.7% lower all-cause mortality
  - NNTT 320
- Drawbacks
  - False positive results
    - Unnecessary scans, biopsies, stress and anxiety
  - Radiation exposure
    - Induced cancers: 0.12 to 0.33 per 1,000 screened subjects over a lifetime

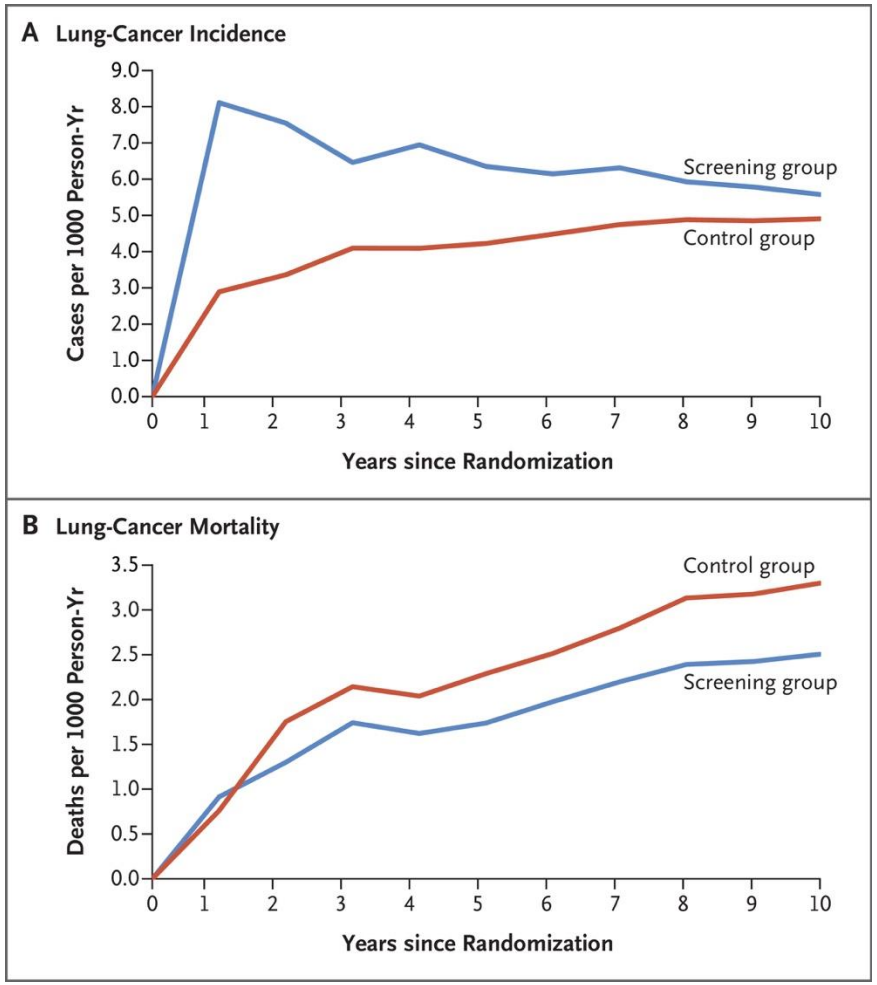

National Lung Screening Trial Research Team, Aberle DR, Adams AM, Berg CD, et al. Reduced lung-cancer mortality with low-dose computed tomographic screening. *N Engl J Med*. 2011

Benign lung tumors

Solitary Tumors	Other Solitary Tumors	Multiple Tumors
Epithelial tumors	Alveolar adenoma	Benign metastasizing leiomyoma
Clara cell adenoma	Pulmonary paraganglioma—chemodectoma	Lymphangioleiomyomatosis
Mucus gland adenoma	Glomus tumor	Cystic fibrohistiocytic tumors
Oncocytoma	Nodular amyloid	
Squamous papilloma	Pleomorphic adenoma—mixed tumor	
Soft tissue tumors	Pulmonary meningioma	
Cavernous hemangioma	Sclerosing hemangioma—pneumocytoma	
Chondroma	Sugar tumor—benign clear cell tumor	
Fibroma fibrous polyp	Teratoma	
Fibromyxoma		
Inflammatory myofibroblastic tumor/ plasma cell granuloma		
Granular cell myoblastoma		
Hamartoma		
Leiomyoma		
Lipoma		
Neurilemmoma—schwannoma		
Neurofibroma		
Pulmonary hyalinizing granuloma		

Metastatic cancers to the lung

Share of synchronous lung metastases by primary site

SEER 2010–2015 • includes primary lung cancers

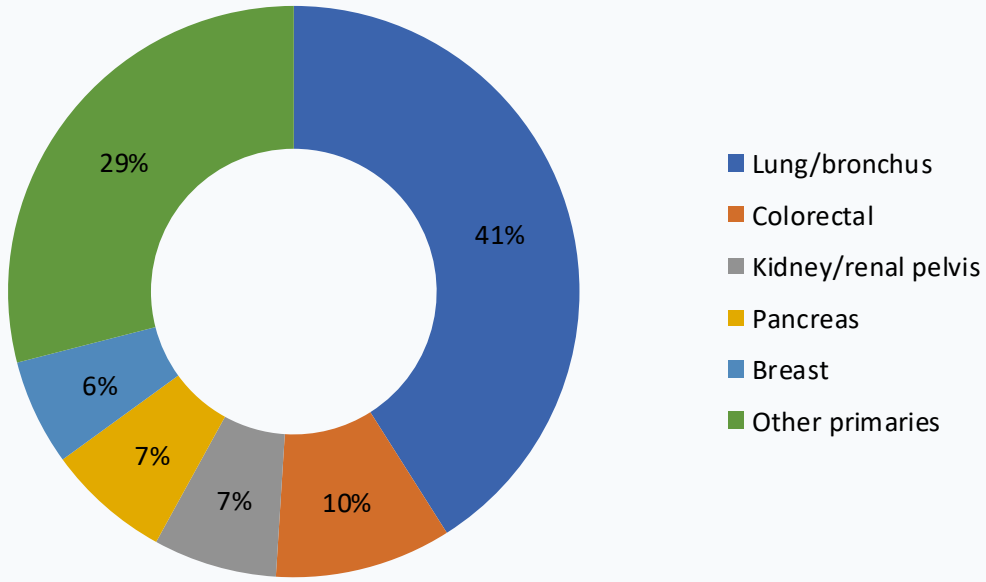

High propensity for pulmonary spread

Osteosarcoma	~38–95%
Renal cell carcinoma	~55–75%
Melanoma	~48–70%
Soft-tissue sarcoma	~66%
Testicular cancer	~40–50%
Hepatocellular carcinoma	~37–70%
Pancreatic cancer	~40%
Head & neck cancer	~12–41%

Common ≠ highest propensity

Barta et al., The Epidemiology of Lung Metastases, Front Med 2021 (SEER 2010–2015); Chudgar et al./reviewed epidemiologic data summarized in The Epidemiology and Biology of Pulmonary Metastases, J Thorac Dis 2021

Mediastinal Tumors

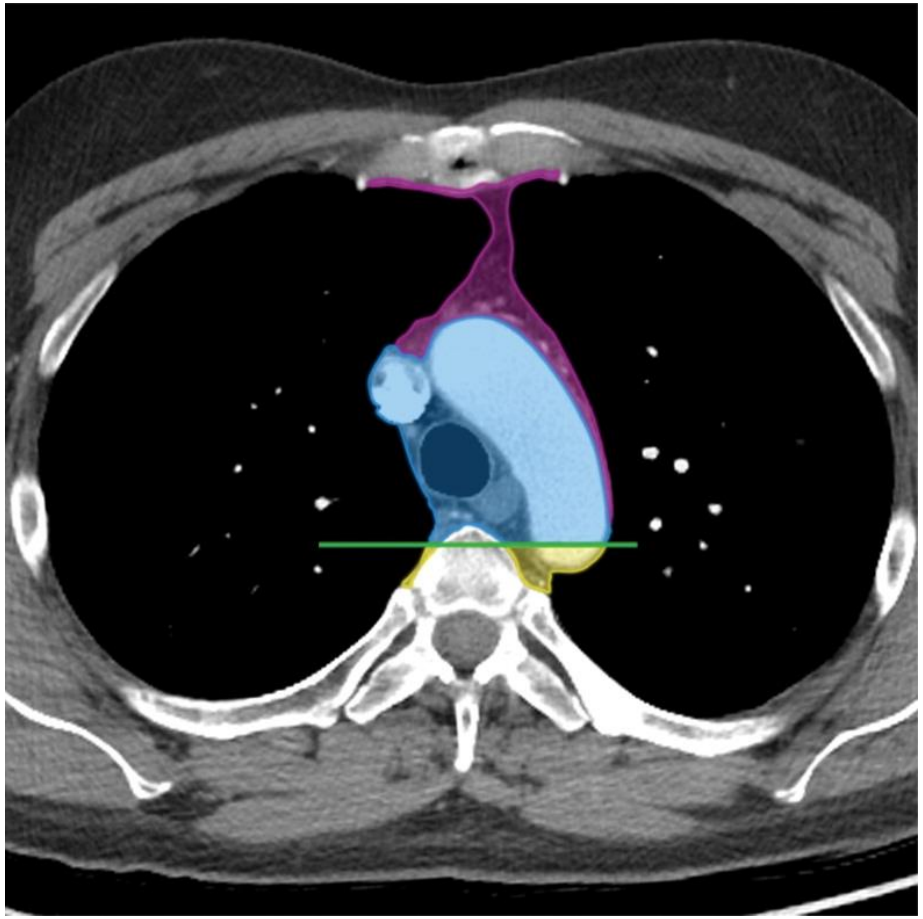



Mediastinal Tumors and masses

PREVASCULAR (Anterior)

"4 Ts":

- Thymic epithelial tumor
- Teratoma / germ-cell tumor
- "Terrible" lymphoma
- Thyroid / intrathoracic goiter

VISCERAL (Middle)

- Lymphadenopathy (common)
  - Malignant,
  - Granulomatous/infectious
  - Reactive
- Bronchogenic/duplication cyst
- Tracheal or esophageal lesion
- Vascular abnormality
- Pericardiac cyst

PARAVERTEBRAL (Posterior)

Think neurogenic first:

- Schwannoma / neurofibroma
- Sympathetic-chain tumors

Others:

- Paravertebral infections/abscess
- Bone neoplasms/metastasis
- Extramedullary hematopoiesis
- Esophageal lesions
- Posterior mediastinal LNs

Localization dramatically narrows the differential before you order a biopsy.

Carter BW, Benveniste MF, Madan R, et al. ITMIG classification of mediastinal compartments and multidisciplinary approach to mediastinal masses. *RadioGraphics*. 2017;37(2):413–436. doi:10.1148/rg.2017160095

Anterior Mediastinal Tumors

Age + CT composition + serum markers often point to the diagnosis

THYMIC

Thymoma: smooth/lobulated solid mass

Invasion → think thymic carcinoma or advanced thymoma

Clinical clue: myasthenia gravis

MRI

GERM-CELL

Fat + fluid + calcification → mature teratoma

Check AFP + β-hCG in young men

Elevated AFP → nonseminomatous GCT until proven otherwise

LYMPHOMA

Bulky, often multi-station nodes

Tissue diagnosis required: EBUS/EUS/Mediastinoscopy /VATS

Hodgkins may require excisional bx

THYROID

Continuity with cervical thyroid

Intense enhancement

Calcification may help

Mediastinal Mass — CT Clues Worth Remembering

WHAT IS IT MADE OF?

- Fat → teratoma, thymolipoma
- Fluid → cyst
- Calcification → teratoma, treated lymphoma, thyroid, thymic lesions
- Enhancing vessels → vascular lesion until proven otherwise

HOW DOES IT BEHAVE?

- Smooth / encapsulated → often indolent
- Irregular invasion → malignancy more likely
- Neural foramen extension → neurogenic tumor

WHEN MRI HELPS

- Cystic vs solid characterization
- Thymic hyperplasia vs tumor
- Neural foraminal / spinal canal involvement

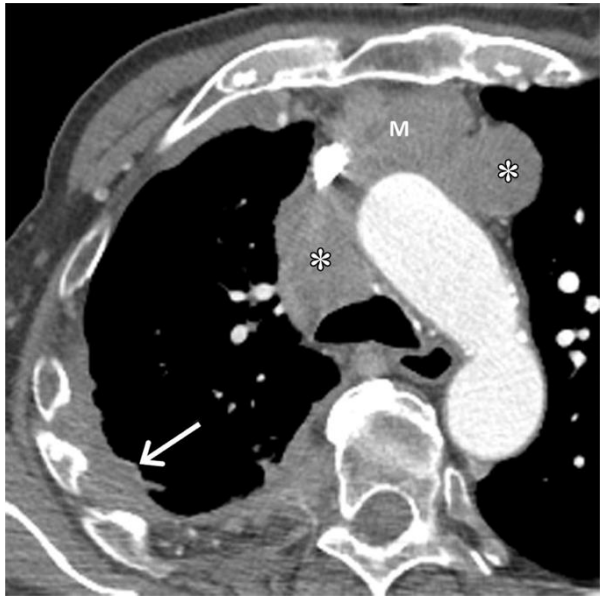

Thymic carcinoma

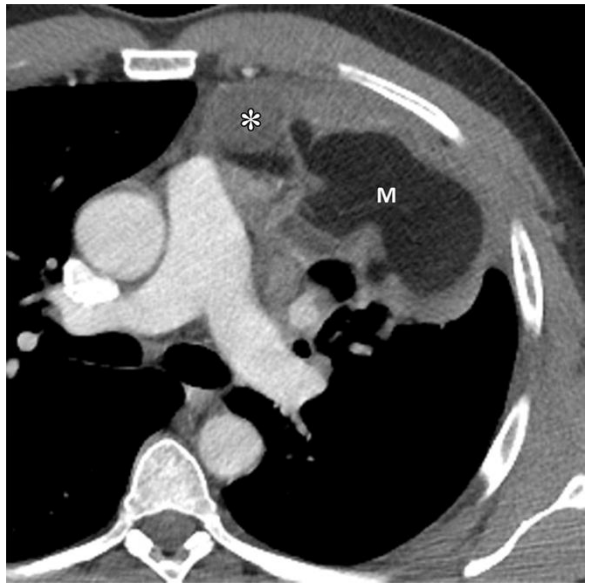

Teratoma



Lymphoma



Goiter

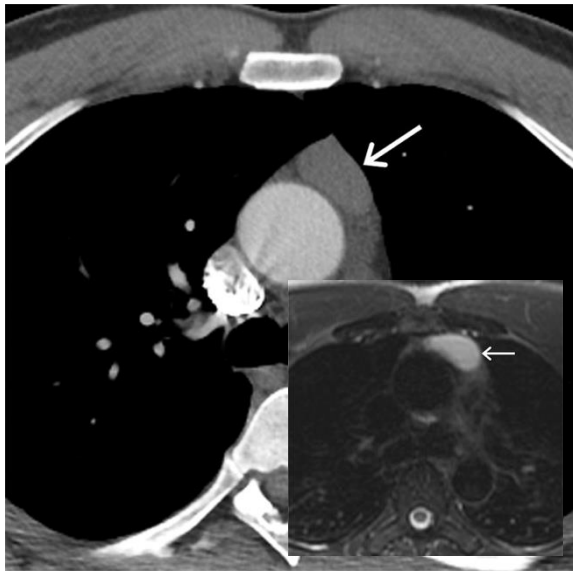

Thymic cyst

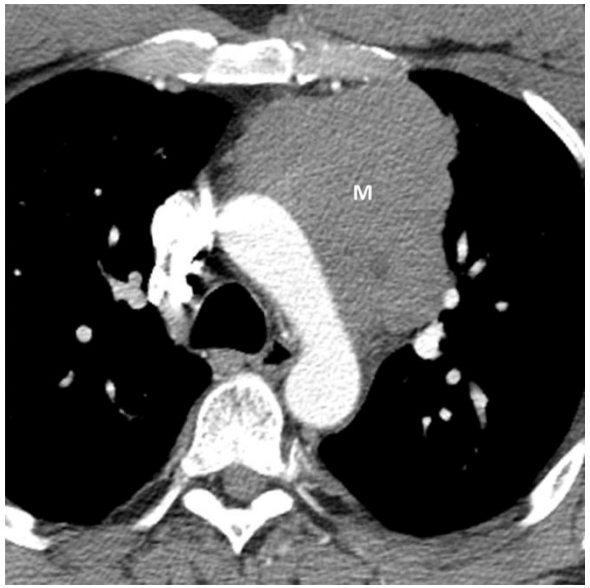

Seminoma

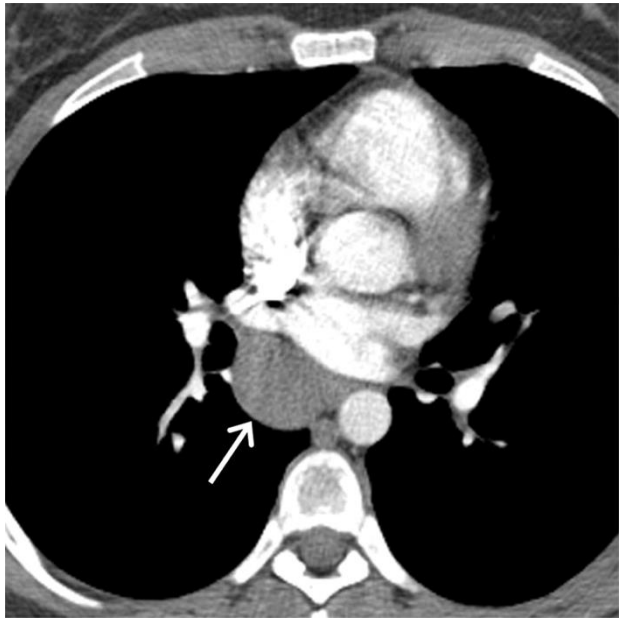

Bronchogenic cysts (0-20 HU)



Esophageal duplication cyst

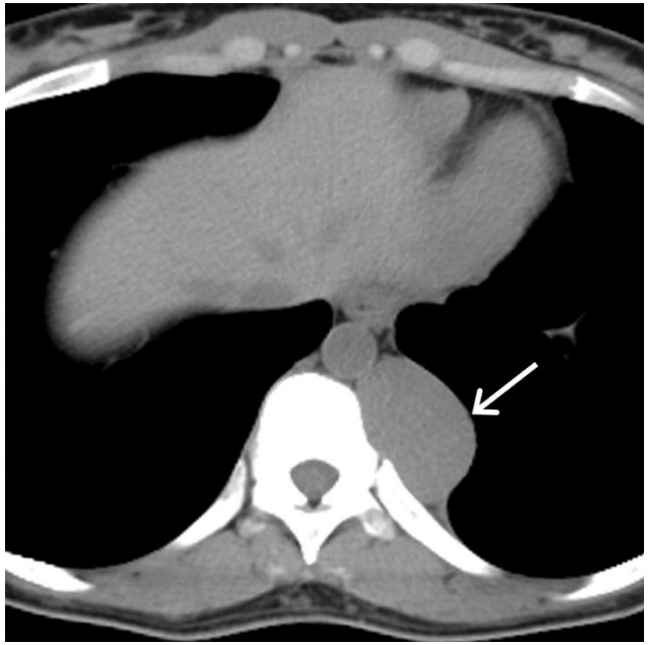

Peripheral nerve sheath tumor

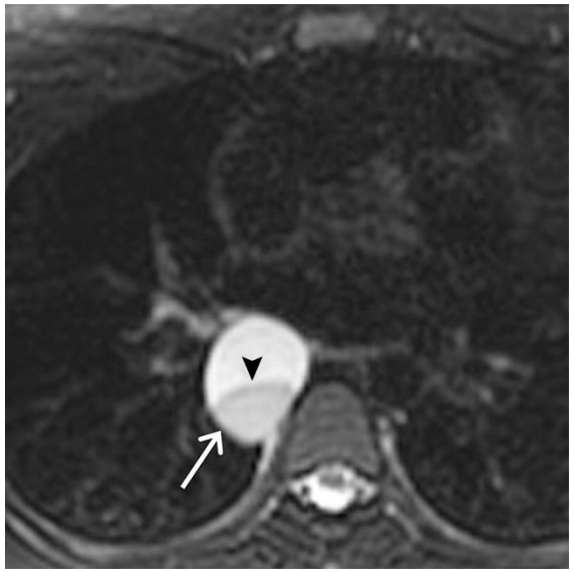

Bronchogenic cyst MRI

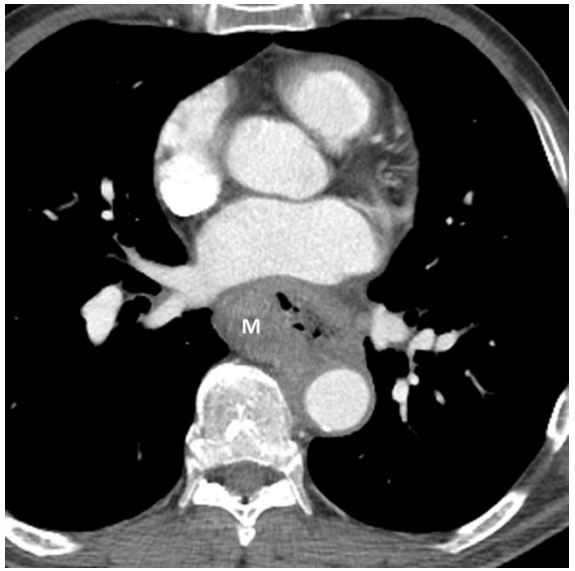

Esophageal cancer

Biopsy or Surgery? — Avoid the Reflex Needle

The diagnosis you suspect determines the next step

BIOPSY FIRST

- Suspected lymphoma
- Unresectable / invasive malignancy
- Metastatic disease
- Germ-cell tumor when markers/imaging do not establish diagnosis

MAY GO DIRECTLY TO RESECTION

- Classic, clearly resectable thymic epithelial tumor
- Resectable mature teratoma
- Discuss in multidisciplinary thoracic team

PULMONARY PEARLS

- EBUS/EUS: excellent for mediastinal lymph nodes
- Anterior prevascular masses may require CT-guided/core or surgical biopsy
- For lymphoma: obtain enough tissue for architecture + flow cytometry

Pleural Tumors

- Most pleural malignancy is metastatic; primary pleural tumors are much less common

Pleural Tumors — A Practical Classification

MESOTHELIAL

- Diffuse pleural mesothelioma
- Localized pleural mesothelioma
- Mesothelioma in situ
- Well-differentiated papillary mesothelial tumor
- Adenomatoid tumor

MESENCHYMAL

- Solitary fibrous tumor (SFT)
- Calcifying fibrous tumor
- Synovial sarcoma
- Other rare sarcomas / vascular tumors

SECONDARY / OTHER

- Metastatic carcinoma (most common)
  - Common primaries: lung, breast, ovary, GI
- Lymphoma
- Direct invasion from lung / chest wall

WHO Classification of Tumours Editorial Board. Thoracic Tumors. 5th ed. IARC; 2021. Sauter JL et al. J Thorac Oncol. 2022;17:608–622.

Pleural Mesothelioma

CLUES

- Strong association with asbestos exposure
- Long latency after exposure
- Dyspnea, chest pain, recurrent effusion

CT: unilateral nodular pleural thickening, fissural involvement, encasement / volume loss

HISTOLOGY

Three major subtypes:

- Epithelioid — most common; better prognosis
- Biphasic
- Sarcomatoid — poorer prognosis

DIAGNOSIS

- Cytology alone often insufficient
- Thoracoscopic pleural biopsy often provides best tissue

IHC supports lineage + malignancy

- Mesothelial markers: calretinin, WT1, D2-40
- BAP1 / MTAP loss or CDKN2A deletion supports malignancy

If mesothelioma is strongly suspected, think beyond fluid cytology — obtain enough pleural tissue for architecture and IHC.

Sauter JL et al. J Thorac Oncol. 2022;17:608–622. NCI Malignant Mesothelioma PDQ.

Solitary Fibrous Tumor of the Pleura

A fibroblastic tumor — not a mesothelioma

CLASSIC PICTURE

- Usually a solitary, well-circumscribed pleural mass
- Often arises from visceral pleura
- May be pedunculated
- Can become very large before symptoms
- Usually no asbestos association

DIAGNOSIS

- CT: sharply defined, lobulated, often enhancing mass
- Larger lesions may show necrosis / heterogeneity

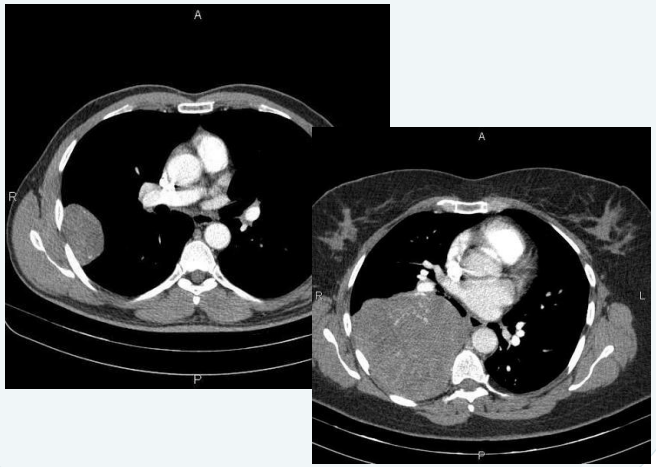

TREATMENT/PROGNOSIS

- Most behave indolently, but malignant behavior can occur

Risk increases with: size, mitoses, necrosis, older age

- Complete surgical resection is treatment of choice
- Long-term follow-up: late recurrence can occur

Hypoglycemia + a giant pleural mass → think SFT: IGF-II–mediated Doege–Potter syndrome.

QUESTIONS?